

## Tubercular Aortitis - A Pictorial Review

Chetana R Ratnaparkhi<sup>1</sup>, Sushupti M Chaukhande<sup>2</sup>

### ABSTRACT

Tuberculous aortitis is a rare disease entity indicative of disseminated tuberculosis. We report a case who presented with newly diagnosed hypertension along with tuberculous lymphadenitis. Tuberculous aortitis should be included in the list of differential diagnosis for secondary hypertension, especially if the patient has a recent disease history of pulmonary tuberculosis.

**Key words :** Tubercular, aortitis, CT angiography.

### Introduction :

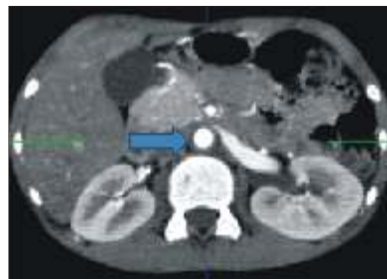Aortitis is a general term that refers to a broad category of infectious or noninfectious conditions in which there is abnormal inflammation of the aortic wall<sup>1</sup>. Tubercular aortitis is a rare entity that is invariably indicative of disseminated tuberculosis<sup>2</sup>. The prevalence of tuberculous aortitis is expected to increase with the rise in M. tuberculosis infection due to the rise in co-infection with HIV and multiple drug resistant tuberculosis<sup>1</sup>. It occurs in less than 1% of patients with latent tuberculosis, with mortality rates as high as 60%<sup>3</sup>. The clinical manifestations are usually vague and nonspecific<sup>1</sup>. As a result, aortitis is often overlooked during the initial work-up of patients with constitutional symptoms and systemic disorders<sup>1</sup>. Noninvasive cross-sectional imaging modalities such as magnetic resonance (MR) angiography, and computed tomographic (CT) angiography play a critical role in initial evaluation and further assessment of aortitis<sup>1</sup>. Here, we present a rare case of tubercular aortitis which was suspected on clinical examination and diagnosed on CT angiography. Multidetector computed tomography (CT) has largely replaced conventional angiography<sup>1</sup>. CT angiography has excellent spatial resolution and is commonly the initial imaging study performed. In this article, the imaging manifestations of a case of tubercular aortitis have

been discussed.

### Case Report :

A 13 years old boy, presented with the complaints of generalized body ache, fever and swelling in the neck since 4-5 days. Patient There was no past history of tuberculosis. Onexamination Patient was mildly febrile, Pulse was 96/min & BP (130/90) which falls in hypertensive range for that age. He also had bilateral cervical and axillary lymphadenopathy. Rest of general and systemic examination was unremarkable. USG abdomen revealed multiple pre and para-aortic lymph nodes with loss of fatty hilum. FNAC from the neck swelling was suggestive of chronic granulomatous inflammation. Cytological features favoured tubercular lymphadenitis. Her CT aortic angiography revealed thickening of wall of aorta (*figure 1*), reduction in caliber of aorta just below origin of renal arteries (*figure 2*), Narrowing of caliber of bilateral renal arteries just after their origin (*figure 3*), Narrowing of caliber of SMA just after its origin (*figure 4, 5*). These imaging features along with the history of tubercular lymphadenitis were consistent with the diagnosis of tubercular aortitis.

**Figure 1 : Axial CT Angiography image showing thickening of the wall of the abdominal aorta**

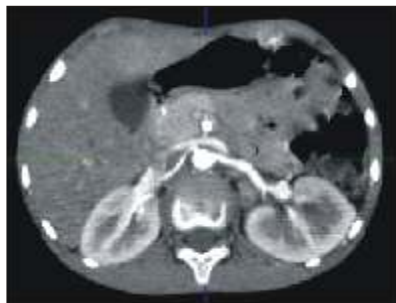

<sup>1</sup>Associate Professor, <sup>2</sup>Junior Resident  
NKPSIMS & RC, Nagpur

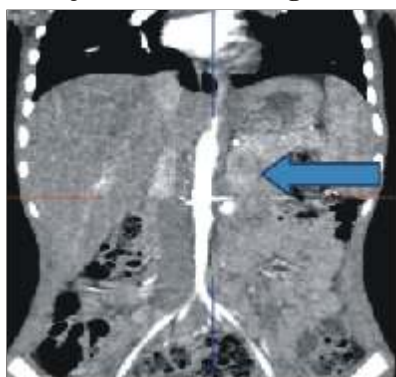
#### Address for Correspondence -

Dr. Sushupti M. Chaukhande  
E-mail : sushupti90@gmail.com

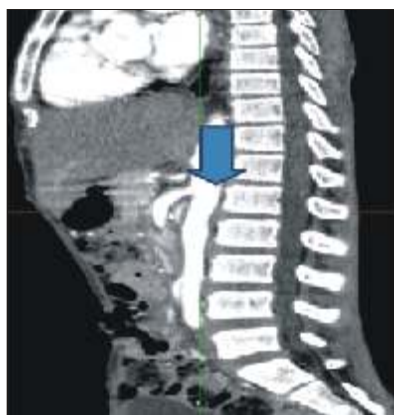
**Figure 2 :**



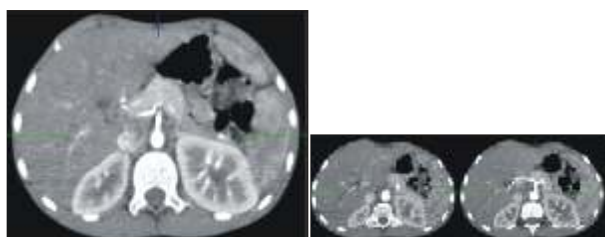
**Figure 3 : Axial and coronal CT angiography image shows Narrowing of caliber of bilateral renal arteries just after their origin.**



**Figure 4 : Sagittal - CT angiography**



**Figure 5 : Axial - CT angiography**



**Discussion :**

The most common causes of aortitis are the large vessel vasculitides - giant cell arteritis (GCA) and Takayasu arteritis<sup>4</sup>. Takayasu arteritis is an autoimmune disorder which typically affects the descending abdominal aorta and presents as pulseless disease due to occlusion of the vessels. Tubercular aortitis is a rare entity that is invariably indicative of disseminated tuberculosis<sup>2</sup>. The prevalence of tuberculous aortitis is expected to increase with the rise in M. tuberculosis infection due to the rise in co-infection with HIV and multiple drug resistant tuberculosis<sup>1</sup>. Tuberculous aortitis usually involves the distal aortic arch and descending aorta as seen in our case<sup>1</sup>. It is generally due to direct extension from contiguous mediastinal lymph nodes, empyema, or pericarditis or to hematogenous or lymphatic spread of distant infection<sup>1</sup>. It occurs in less than 1% of patients with latent tuberculosis, with mortality rates as high as 60%<sup>3</sup>. In a patient with tuberculosis and thickening of the aortic wall, the possibility of tubercular aortitis is likely.

The risk of perforation increases when a cold abscess is present<sup>5</sup>. In a study of 39 cases of tuberculomycotic aneurysms by Long et al<sup>6</sup>, 75% of the aneurysms appeared to originate from aortic wall erosion by a contiguous focus; most of the aneurysms (90%) were saccular and false, and disseminated tuberculosis was present in almost one-half of cases. Involves the distal aortic arch and descending aorta. Prevalence is on increase with rise in co-infection with HIV and multiple drug resistant tuberculosis

**Conclusion :**

We present a case of Tubercular aortitis which is a rare entity that is invariably indicative of disseminated tuberculosis. Tubercular aortitis occurs in less than 1% of patients with latent tuberculosis, with mortality rates as high as 60%. Multidetector computed tomography (CT) has largely replaced conventional angiography. CT angiography has excellent spatial resolution and is commonly the initial imaging study performed.

**References :**

1. Carlos S. Restrepo, MD Daniel Ocazonez, MD Rajeev Suri, MD Daniel Vargas, MD; Aortitis : Imaging Spectrum of the Infectious and Inflammatory Conditions of the Aorta *RadioGraphics* 2011; 31:435-451.
2. Zakeya A. Bukhary, Abdulrahman A. Rajhi,; tubercular aortitis; *ann Saudi med* 26; jan-feb 2016.
3. Allins AD, Wagner WH, Cossman DV, Gold RN, Hiatt JR. Tuberculous infection of the descending thoracic and abdominal aorta: case report and literature review. *Ann Vasc Surg* 1999;13(4):439-444.
4. Heather L. Gornik, M.D., M.H.S. and Mark A. Creager, M.D. Aortitis *Circulation*. 2008 June 10; 117 (23) : 3039-3051. Doi:10.1161/CIRCULATIONAHA.107.760686.
5. Choi JB, Yang HW, Oh SK, Yun KJ. Rupture of ascending aorta secondary to tuberculous aortitis. *Ann Thorac Surg* 2003;75(6):1965-1967.
6. Long R, Guzman R, Greenberg H, Safneck J, Hershfield E. Tuberculous mycotic aneurysm of the aorta : review of published medical and surgical experience. *Chest* 1999; 115 (2) : 522-531.