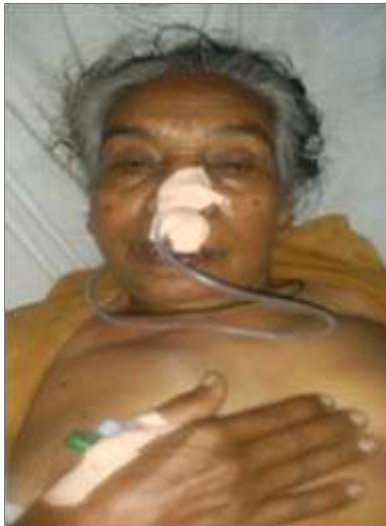

A Case of Large Diaphragmatic Hernia in Adult

Somalwar A.¹, Somkuwar K.², Durgam S.², Dhagadi S.³



Patient with large diaphragmatic hernia

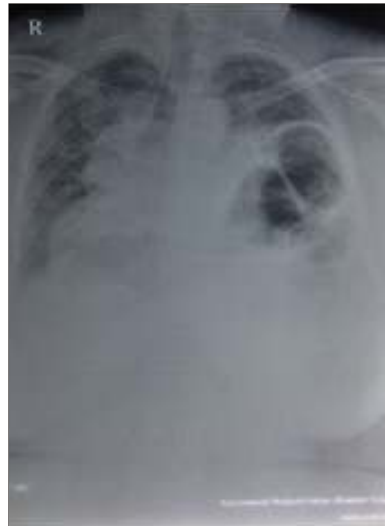

Figure 1 : X-Ray Chest PA showing bowel shadows in left hemi-thorax (10/03/2014)

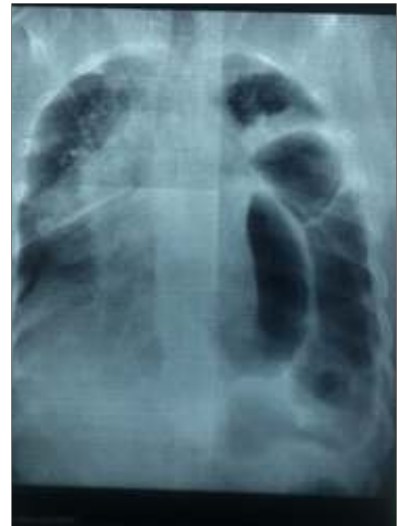

Figure 2 : X-Ray Chest PA showing bowel loops in left hemi-thorax with left lung collapse and mediastinal shift (11/03/2014)

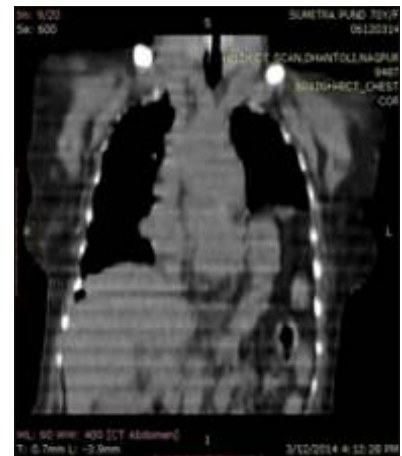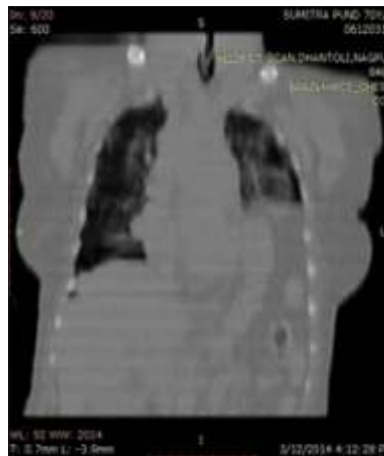
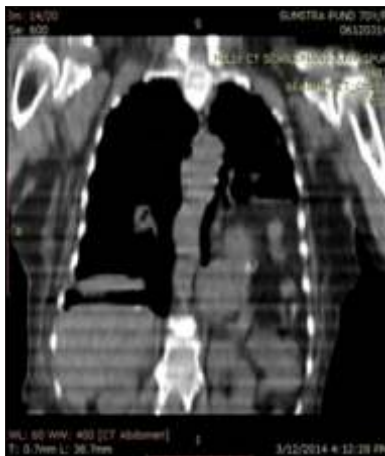


Figure 3 : HRCT THORAX showing large left sided diaphragmatic hernia with herniation of stomach, left colon and spleen in left hemithorax (12/03/2014)

¹Associate Professor, ²Assistant Professor, ³Resident
Department of Medicine, GMC, Nagpur

Address for Correspondence -

Dr. Ashutosh Somalwar
E-mail : amsomalwar@gmail.com

A sixty four-year-old female patient, a known case of systemic hypertension and diabetes mellitus type 2 was admitted to GMCH, Nagpur as a case of drug Induced hypoglycaemia and treated successfully with 25% dextrose. On the next day morning, patient started complaining of breathlessness, more on lying down position. On examination, patient was

dyspnoeic, tachypnoeic, SpO₂ 65%, RBS 106 mg/dl and air entry decreased on left side of chest. So, X-ray Chest (*Fig. 1 & 2*) was done which showed bowel loops in left hemi-thorax suggestive of diaphragmatic hernia. Patient's HRCT thorax (*Fig. 3*) was done which suggested large left diaphragmatic hernia with herniation of stomach, left colon and spleen in left hemi-thorax, diffuse ground glass attenuation involving major part of left upper lobe and small area of left lower lobe. There was no history of any cardiorespiratory disease or similar complaint in the past and there was no history of trauma to the chest or abdomen or any surgical procedure in the past. She was never diagnosed as having diaphragmatic hernia. Diaphragmatic hernia is a defect in the diaphragm that allows the abdominal contents to move into the chest cavity. The causes can be congenital

(Morgagni's hernia or Bochdalek hernia), Hiatal hernia, Iatrogenic or Traumatic hernia. Congenital diaphragmatic hernias are an uncommon diagnosis among adult populations because they are mainly recognized in infancy and have high mortality.

Conflicts of interest : None declared

References :

1. Shin M. S., Mulligan S. A., Baxley W. A., Ho K. J. Bochdalek hernia of diaphragm in the adult. *Chest*. 1987;92 : 1098.
2. Chui P. P., Tan C. T. Sudden death due to incarcerated Bochdalek hernia in an adult. *Ann Acad Med Singapore*. 1993;22(1) : 57-60.
3. Sugimura A., Kikuchi J., Satoh M., Ogata M., Inoue H., Takishima T. Bilateral Bochdalek hernias in an elderly patient diagnosed by magnetic resonance imaging. *Intern Med*. 1992; 31 : 281-283.