

Chronic Myeloid Leukemia with Acute Coronary Syndrome

Ankush Toshniwal¹, Shilpa Kuthe², N Humaney³

ABSTRACT

Chronic Myeloid Leukemia (CML) is one of the most common leukemias of the elderly. Chronic myeloid leukemia (CML) is generally diagnosed through physical findings such as pallor and massive splenomegaly associated with marked leukocytosis with pleomorphic picture in peripheral blood smear. CML can manifest as chronic stable phase, accelerated phase or blast crisis. We report a case of Chronic Myeloid Leukaemia-Chronic Phase who went on to develop acute coronary syndrome due to hyperviscosity and leukostasis.

Keywords : Chronic Myeloid Leukaemia, Hyperviscosity, Leukostasis

Introduction :

Chronic myeloid leukemia (CML) is a myeloproliferative neoplasm with clonal hyperproliferation of myeloid cells in the bone marrow associated with a characteristic chromosomal translocation called the Philadelphia chromosome t(9;22)¹. The median age of onset is 40-60 years; however, it may occur in children and elderly persons. CML has three stages : chronic phase (CP); accelerated phase (AP); and blast crisis (BC).

Clinical findings in chronic-phase CML include fatigue, decreased appetite, and massive splenomegaly. Hematological findings include leukocytosis, thrombocytosis, basophilia, and decreased leukocyte alkaline phosphatase (LAP) scores². In accelerated phase or blast crisis patient may have severe generalized bony pains.

Case Report :

A 40 year old female patient presented in Emergency room with complaints of low grade fever since 4-5 days, generalized weakness and backache since 5 days. There was dragging abdominal pain and weight loss. There was no significant h/o systemic hypertension / diabetes mellitus.

On general examination, patient was afebrile with Heart rate of 120/min, BP- 120/70mm Hg, Pallor was present. Respiration was normal. There was no sternal tenderness / petechiae / purpura / peripheral lymphadenopathy / xanthomas / xanthelesmas. On Systemic Examination, patient had massive non tender splenomegaly (18 cm below left costal margin.) without splenic bruit. Other systems were normal.

On admission, complete blood count showed Hb-9.3 gm% TLC-1,49,700/ul with immature myeloid forms (neutrophils 21% lymphocytes 6% eosinophils 11% monocytes 3% basophils 7% band cells 11% blast cells 6% promyelocytes 5% myelocytes 21% metamyelocytes 9%) hematocrit of 22.1% and a platelet count of 3.81 lacks/cu mm, MCV-74, this peripheral picture was suggestive of Chronic Myeloid Leukaemia. ECG and lipid profile at the time of admission were normal. USG was s/o Splenomegaly (32cm x 17.6 cm) Bone marrow aspiration and biopsy was done which showed an increased cellularity with myeloid hyperplasia and marked basophilia and eosinophilia (blast-7% promyelocyte-5% myelocyte-22% metamyelocyte-9% band-11% neutrophils-23% lymphocytes-5% eosinophils-10% basophils-7% monocytes-1%). This picture was consistent with the diagnosis of CML-Chronic Phase. At the same time patients RT-PCR for Philadelphia Chromosome was also sent.

Patient was started on tablet Imatinib 400 mg OD. Analgesics were given for dragging abdominal pain. Subsequently on day 3 of hospitalization, patient developed sudden onset breathlessness and

¹Jr.Resident, ²Lecturer, ³Professor & Head
Department of Medicine, NKPSIMS, Nagpur

Address for Correspondence -

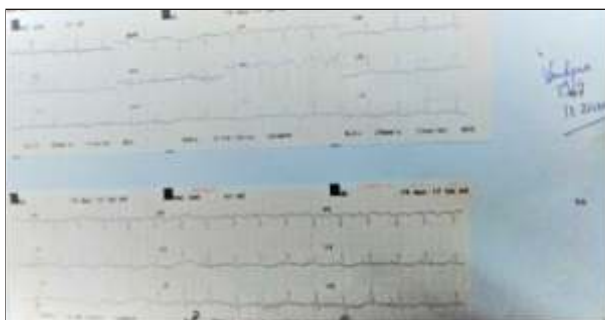Dr. Ankush Toshniwal
E-mail : toshniwalankush@gmail.com

Received on 13th February 2018

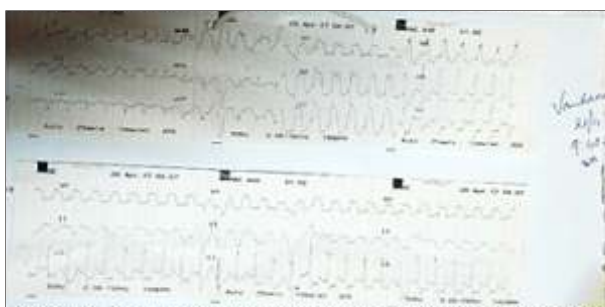Accepted on 17th June 2018

uneasiness. BP was 110/70 mmHg. Respiratory rate was 28/min. 80 % SpO₂ on room air. ECG showed heart rate 100/min, sinus tachycardia with no significant ST-T changes. 2D Echo showed PA pressure 50 mmHg, Right ventricle was dilated, contractility of RV free wall was reduced in relation to apex, Inferior vena cava was dilated 16 x 8 mm, LVEF- 60%. Features s/o Pulmonary Embolism. D-Dimer was 2.2 which was elevated. CT Pulmonary Angiography could not be done due to financial issues. Therapy with low molecular weight Heparin at therapeutic doses was started and she was kept on NIV overnight for respiratory support.

IMAGES (ECG)



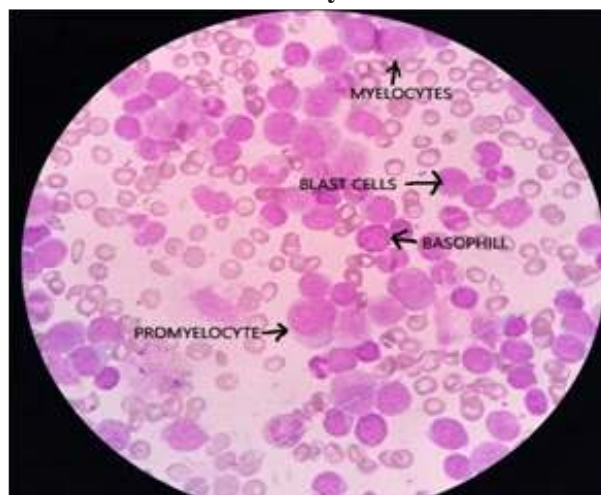
Ecg on Admission which Was normal Except



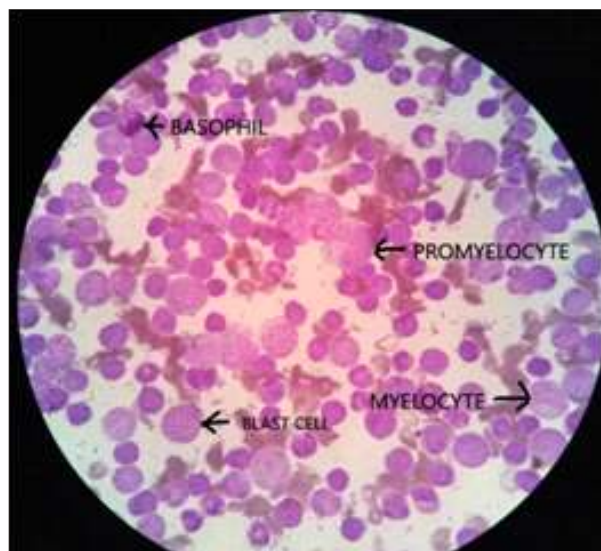
Ecg showing Acute Anterior Wall MI

Subsequently next day early morning, patient developed sudden onset chest pain with worsening of breathlessness and hypotension. ECG at that time revealed acute anterior wall ST segment elevation myocardial infarction (STEMI). Patient's condition worsened and she started rapidly desaturating. She was immediately intubated and put on ventilatory support. Dual antiplatelet agents with statins were given through Ryle's Tube. Cardiologist opinion was taken but she deteriorated so rapidly that no

Sinus tachycardia



P.S. of Our Patient



B.M. Picture of Our Patient

active intervention could be done. Within half an hour Patient succumbed due to cardiogenic shock despite inotropic support.

Discussion :

This case report describes occurrence of Acute MI in the patients of CML Hyperleukocytosis refers to a laboratory abnormality that has been defined as a total leukocyte count greater than 100 x 10⁹ (100,000/uL)⁶. In contrast, leukostasis (also called symptomatic hyperleukocytosis) is a medical emergency most commonly seen in patients with acute myeloid leukemia or chronic myeloid

leukemia in blast crisis. Leukostasis is a pathologic diagnosis in which white cell plugs are seen in the microvasculature. Clinically, leukostasis is typically diagnosed when a patient with leukemia and hyperleukocytosis presents with respiratory distress or neurological symptoms.

Few case reports regarding the presence of pro-coagulant state and development of Acute myocardial infarction (AMI) have been found in the setting of thrombocytosis and hyperleukocytosis. One case report has attributed Acute MI to possible adverse effect of chemotherapy with Hydroxyurea^{3,4,5}. Our patient did not receive hydroxyurea. One case regarding development of AMI after use of Nilotinib (TKI) has been found although the exact mechanism has not been clearly understood. Few case studies were also published regarding development of Cardiovascular Events in patients of CML who were taking Tyrosine Kinase Inhibitors (TKIs) mainly 2nd and 3rd generation like Dasatinib and Ponatinib^{7,8}.

In our patient who came with massive splenomegaly and PS suggestive of CML the patient was immediately started on Imatinib. She was further treated with LMWH and NIV was initiated for hypoxia due to suspicion of Pulmonary Embolism. However, sudden worsening of general condition occurred and patient developed Acute MI. She succumbed due to cardiogenic shock before any active intervention could be offered. The patient's peripheral blood RT-PCR which had been sent on admission was positive for Philadelphia Chromosome.

In our patient Acute Myocardial Infarction was seen as a rare manifestation of hyper viscosity syndrome in CML She had none of the traditional risk factors

for coronary artery disease. In review of literature, most acute coronary events have been described secondary to treatment initiated for CML.

Conclusion :

Acute Myocardial Infarction is a rare manifestation of hyperviscosity syndrome in CML. The prognosis in concomitant STEMI and CML is clearly worse than that of either pathologic condition individually. If patients are too frail to undergo emergent treatment as in our case they can die within hours or days.

Acknowledgment :

Department of Pathology NKP SIMS and RC Nagpur for providing slides of PS and BM.

No conflicts of Interest.

References :

1. Kantarjian H, Cortes J (2013) Chronic myeloid leukemia. Niederhuber JE, Armitage JO, Dorohow JH (eds). *Abeloff's Clinical Oncology*. (5th edn). Philadelphia, USA.
2. Sawyers CL. Chronic myeloid leukemia. *N Engl J Med* 1999;340:1330-40.
3. S. Sharma, D. Marini Acute myocardial infarction in a patient with chronic myelogenous leukemia *Annals of Hematology*, 1996, Volume 72, Number 3, Page 153.
4. H. Kälsch, H. Wieneke, R. Erbel Acute myocardial infarction in a patient with chronic myelocytic leukemia during chemotherapy with hydroxyurea *Herz*, 2010, Volume 35, Number 6, Page 420.
5. Bergeron GA, Datnow B. Acute Myocardial Infarction Due to Chronic Myelogenous Leukemia *Chest* Volume 65, Issue 4, April 1974, Pages 452-455.
6. Piro E, Carillio G, Levato L, Kropp M, Molica S. Reversal of leukostasis-related pulmonary distress syndrome after leukapheresis and low-dose chemotherapy in acute myeloid leukemia. *J Clin Oncol*. 2011;29:e725-e726. [PubMed]
7. Moslehi JJ, Deininger M. Tyrosine Kinase Inhibitor Associated Cardiovascular Toxicity in Chronic Myeloid Leukemia. *Journal of Clinical Oncology*. 2015;33(35):4210-4218. doi:10.1200/JCO.2015.62.4718.
8. Aghel N, Delgado DH, Lipton JH. Cardiovascular toxicities of BCR-ABL tyrosine kinase inhibitors in chronic myeloid leukemia: preventive strategies and cardiovascular surveillance. *Vascular Health and Risk Management*. 2017;13:293-303. Doi:10.2147/VHRM.S108874.