

**Case Report****Albright's Hereditary Osteodystrophy : A Case Report****Bothara R V<sup>1</sup>, Holay M P<sup>2</sup>, Raut K U<sup>3</sup>, Nayak G P<sup>1</sup>, Kadbe A P<sup>1</sup>, Deshpande A<sup>1</sup>****ABSTRACT**

Patients with Pseudohypoparathyroidism 1a (PHP-1a) have a typical phenotype, described for the first time by Albright, and therefore called Albright's Hereditary Osteodystrophy (AHO). It is characterized by a round face, flat, wide and low nasal bridge, short neck, obesity, short stature, subcutaneous calcifications and skeletal abnormalities. There is resistance to parathormone, mainly characterized by hypocalcemia, increased serum parathormone concentration and hyperphosphatemia. Sometimes, PHP can present with hypocalcaemia related seizures. Here is a case report of 13-year-old female patient, who presented with recurrent generalised tonic clonic seizure (GTCS) along with classical features of AHO.

**Key words :** Pseudohypoparathyroidism, Albright's Hereditary Osteodystrophy

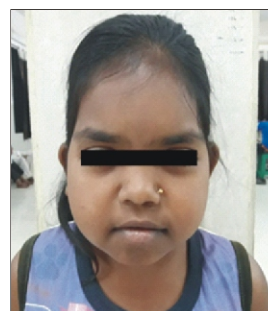**Introduction :**

Pseudohypoparathyroidism (PHP) is characterized by inability of the body to respond appropriately to parathormone. It is characterized by increased serum parathormone concentration, hypocalcemia and hyperphosphatemia. AHO when seen in association with resistance to parathormone (PTH), it is called PHP. Here is, a case report of 13-year-old female patient with AHO with distinctive physical characteristics and oral manifestations.<sup>1</sup>

**Case Report :**

A 13 year old female presented to OPD with chief complaints of generalised tonic clonic seizures (GTCS), 5-6 episodes and low grade fever a day prior to hospitalization. There was no h/o vomiting, headache, altered sensorium, motor weakness of any limb or visual complaints. Her past history revealed that she was hospitalized for evaluation of short stature 2 years back & was diagnosed to have hypothyroidism and was on thyroid replacement therapy. She had history of seizures, 2-3 episodes six months back but was not on anticonvulsants. Family history revealed that her mother was also short statured.

On examination, she was obese, short statured (ht - 112 cm, wt - 40 kg, BMI - 32 kg/m<sup>2</sup>). She had typical phenotypic features. Round facies, low set ears, depressed nasal bridge, brachydactyly and brachymetatarsia. (*Fig. 1,2,3*) Examination of oral cavity showed dental caries, malocclusion of teeth impaired dentition. She also had classical "knuckle dimple dimple sign" (*Fig. 4*) Her systemic examination revealed no significant abnormality except for pseudohypertrophy of calf muscles. She had delayed bone age of 11 years according to Greulich and Pyle chart.<sup>2</sup>

**Figure 1 : Round Facies****Figure 2 : Brachydactyly**

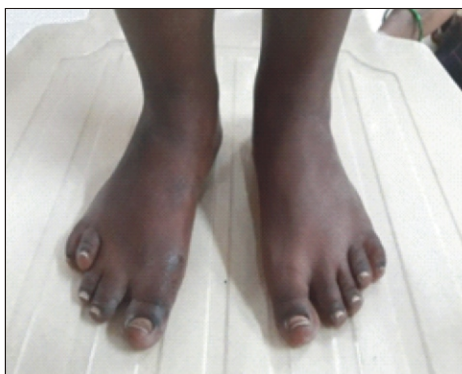<sup>1</sup>Resident, <sup>2</sup>Associate Professor, <sup>3</sup>Assistant Professor, Department of Medicine, Government Medical College, Nagpur

**Address for Correspondence -**

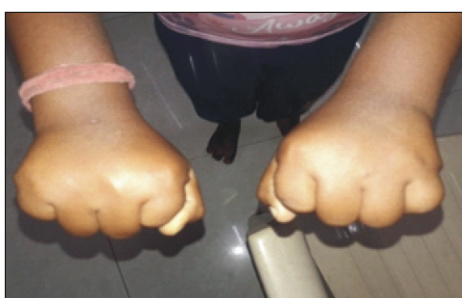
Dr. Madhuri Holay  
E-mail : mpholay@gmail.com

Received on 31st May 2019

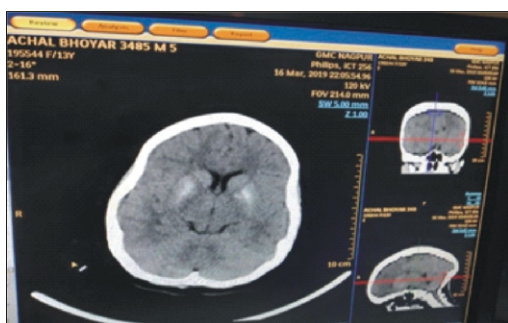
Accepted on 10th June 2019



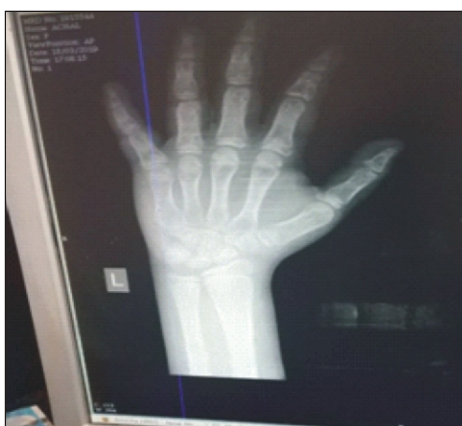**Figure 3 : Brachymetatarsia**



**Figure 4 : Knuckle knuckle dimple sign**



**Figure 5 : Bilateral basal ganglia calcification**



**Figure 6 : Shortened 4th and 5th metacarpals**

On investigation her Hb - 6.9 gm%, TLC-5000/cmm, Platelets-4 lac. MCV was 65 fl. Renal and Liver functions were normal except for raised ALP 339 IU/dl. Serum Sodium and Potassium were normal.

Ultrasound abdomen did not show any abnormality. USG thyroid was suggestive of bulky and heterogenous thyroid, Fundus examination was normal, Thyroid Function Test on 25 mcg thyroxine replacement was T3-3.77, T4-2.34, TSH-0.337. Her serum total calcium was low 7.01 mg/dl, ionic calcium was 0.83 mg/dl (Normal range), Serum Phosphorus was 6.8 mg/dl (Normal range), Serum Mg was normal 2.34 meq/l.

Her plain CT Head showed bilateral symmetrical basal ganglia calcification. (**Fig. 5**)

X-ray of both hands revealed positive Archibald's sign i.e. shortened 4th and 5th metacarpals. (**Fig. 6**)

We entertained the possibilities of Hypoparathyroidism, Pseudohypoparathyroidism, Kocher Debre Semelaigne Syndrome (hypothyroidism associated with pseudomuscular hypertrophy, short stature and cretinism). Her PTH level was sent. It was raised 269 ng/l (Normal range 10-65 ng/dl).

The biochemical profile along with characteristic phenotype supported the diagnosis of Pseudohypoparathyroidism type Ia (Albright's Hereditary Osteodystrophy). Genetic testing for GNAS mutation could not be performed in our case. She was initiated on thyroxin, antiepileptics & calcitriol along with calcium supplements and was advised follow up with measurement of serum calcium, phosphorus, parathyroid hormone and thyroid-stimulating hormone levels for titration of therapy.

#### **Discussion :**

Pseudohypoparathyroidism (PHP) is a rare congenital disorder. A Japanese study estimated prevalence of the disorder to be 7.2 per million only<sup>3</sup>. PHP occurs approximately twice as frequently in females as in males. It is characterized by impairment of the parathyroid hormone (PTH) signaling pathway, with target organ resistance to the action of PTH. PTH exerts its actions by binding

to a transmembrane G-protein-coupled receptor, activating cAMP formation. The classical form of PHP, pseudohypoparathyroidism type 1A (PHP1A), which is associated with Albright's hereditary osteodystrophy (AHO), is caused by de novo or autosomal dominantly inherited inactivating mutations within the Gs alpha subunit-coding GNAS gene on chromosome 20 q13.3. The maternal allele is the predominant source of Gs alpha - expression in the proximal renal tubule, thyroid, pituitary, and gonads, since paternal expression is silenced in these tissues; in other tissues, however, expression is biallelic. Therefore, an inactivating mutation causes PHP1A (AHO clinical features and hormone resistance) in the case of maternal inheritance, while the same mutation on the paternal allele results in AHO clinical features only, a condition known as pseudo-pseudo-hypoparathyroidism (PPHP).<sup>4</sup>

The biochemical changes of hypocalcemia and hyperphosphatemia are caused by resistance towards PTH in the proximal renal tubules, which leads to reduced or inappropriately normal synthesis of 1,25 (OH) 2 vitamin D as well as impaired down-regulation of NPT2a and NPT2c expression, and thus reduced urinary phosphate excretion. PHP1A patients often develop target-organ resistance to other hormones that act through Gs alpha -coupled receptors, particularly TSH; resistance to gonadotrophins and GHRH is also reported<sup>5</sup>. In some patients with AHO, hypothyroidism may be an early manifestation, as present in our case and the diagnosis of AHO should be considered in the evaluation of childhood primary hypothyroidism, particularly, if there is no goiter, hypoplasia or ectopic thyroid tissue.<sup>6</sup>

PHP1A is characterized by phenotypic findings referred to as Albright Hereditary Osteodystrophy (AHO), which short stature, obesity, round face, shortening of the metacarpus and metatarsus (most frequently the 4th and 5th ones), calcification in the subcutaneous tissue, short neck, low nasal bridge, mental retardation, cataract, hyperphosphatemia, cone-shaped epiphysis, and osteoporosis.<sup>7</sup> These patients have early onset obesity, and varying degrees of developmental delays and cognitive

impairment. Oral manifestations include aplasia, thin enamel with enlarged pulp chamber, hypoplasia, hypodontia, pulp calcification, multiple carious teeth, multiple unerupted teeth, crowded anterior teeth, anterior open bite, gingival hyperplasia, gingivitis with spontaneous bleeding and pain<sup>5</sup>. Most of these features were present in our case. The age and mode of presentation are unpredictable. Some patients present with classical symptoms of hypocalcemia (tetany, seizures) during infancy, while others present with short stature during later life. The dysmorphic features may be absent at presentation and may evolve during childhood. There is considerable phenotypic variability of the disease in the same family and the same generation. In contrast, most patients affected by pseudohypoparathyroidism type 1B (PHP1B) present with PTH-resistance alone without the typical phenotypic features, but they may also show resistance to other hormones, and some have the phenotypic changes classically associated with PHP1A<sup>6</sup>. The diagnosis is based on clinical and biochemical characteristics, which will vary according to the age of the patient. The diagnosis of AHO should be based on the presence of major criteria (brachydactyly due to premature fusion of the epiphyses and short stature by adulthood) and additional criteria (stocky build, round facies, and ectopic ossifications). Genetic testing for a mutation in the GNAS1 gene can confirm the diagnosis and identify the subtype.

Treatment of PHP is similar to hypoparathyroidism, with oral calcium and calcitriol. Calcitriol allows to overcome the enzymatic blockade and, when associated with calcium, improves hypocalcaemia. The goal is to maintain normocalcemia and to keep serum PTH levels in the upper portion of the reference range, thereby avoiding PTH suppression, which can be associated with hypercalciuria and renal calcification<sup>8</sup>. PTH, calcium, and phosphorus should be evaluated every six months during treatment in asymptomatic patients, and more frequently when clinically indicated. Patients and families should be instructed with regard to the symptoms of hypo- and hypercalcemia.

**Conclusion :**

PHP IA is an uncommon cause of hypocalcemia. Blood electrolytes must be called to mind in case of epilepsy or neurological evidence. Early diagnosis and treatment of PHP prevent complications. Hence, a high index of suspicion should be kept while investigating short stature and hypocalcemia.

Ours was a classical case of AHO with typical phenotypic features. Diagnosis is not always easy since the phenotypic features may not be noticeable at birth and in the first years of life, and may be heterogeneous later on. Endocrine and metabolic changes, although mandatory for the investigation, may not be present or emerging at different times and with varying severity. A high degree of suspicion and multidisciplinary approach is necessary for the early diagnosis, appropriate treatment and lifelong management of the disease and its complications, which have a great impact on patients and their families.

**Conflicts of interest :** None reported by Authors

**Acknowledgement :**

We are thankful to Dr. Parimal Tayde, Consultant Endocrinologist, Superspeciality Hospital, GMC, Nagpur for guiding us in evaluation of this patient. We are also thankful to Professor & HOD Medicine & Dean, GMC, Nagpur for allowing us to publish this case.

**References :**

1. Deepa Hugar, Sangameshwar Sajjanshetty, Santosh Hugar, and Megha Kadani Albright Hereditary Osteodystrophy : A Case Report *J ClinDiagn Resv.*8 (10); 2014 Oct ZD28-ZD30.
2. Greulich WW, Pyle SI. Radiographic Atlas of Skeletal Development of the Hand and Wrist. 2nd ed. Stanford, CA : Stanford University Press 1959 and Hand Bone Age, A Digital Atlas of Skeletal Maturity by Vicente Gilsanz and Osman Ratib ISBN 3-540-20951-4 Springer-Verlag Berlin Heidelberg New York, 2005.
3. P. Mannava A case report of pseudohypoparathyroidism *Indian J ClinBiochem.* 2015 Jan; 30 (1): 113116..Published online 2014 Jul 15. doi: 10.1007/s12291-014-0445-1.
4. John T. Potts, Jr, Harald W Juppner. Disorders of Parathyroid gland & Calcium Homeostasis, harrisons principles of internal Medicine. McGraw Hill publication, 20th Edin vol 2 chapter 403, 2940-2941.
5. Levine MA, Downs RW Jr, Breslau NA, Moses AM, Marx SJ, Lasker RD, Rizzoli RE, Aurbach GD, Spiegel AM. Resistance to multiple hormones in patients with pseudohypoparathyroidism. *Am J Med* 1983; 74(4): 545-556.
6. Kapoor S, Gogia S, Paul R, Banerjee S. Albright's hereditary osteodystrophy. *The Indian Journal of Pediatrics*, 2006; 73 (2) : 153-6.
7. National Organization for Rare Disorders (NORD) [cited 2017 Mar 10]. Available from : <<https://rarediseases.org/rare-diseases/pseudohypoparathyroidism/>>
8. Goswami M, Verma M, Singh A, Grewal H, Kumar G. Albright hereditary osteodystrophy : A rare case report. *J Indian SocPedodPrev Dent.* 2009; 27(3) : 184-8. Doi : 10.4103/0970-4388.57101.