

Zika Virus : A Review for Clinicians

Kharkar S¹

ABSTRACT

Zika virus is a flavivirus related to Dengue virus, yellow fever virus and West Nile virus. It is Considered an emerging arbovirus transmitted by mosquitoes of the genus Aedes. Clinical picture is Characterised as a “dengue-like” syndrome, with abrupt onset of fever and an early onset skin rash, pruritic often.

Nevertheless, until now deaths and complications Caused by the disease are not reported. The rapid spread of the virus and its epidemic potential are especially problematic in countries where there are the circulation of other arboviruses which imposes difficulties in the differential diagnosis and healthcare burden. Control measures are the same recommended for dengue and chikungunya which are based in health education and vector control.

Key Words : Zika Aedes; arboviruses; flavivirus; Flaviviridae Infections.

Introduction :

Zika virus is a flavivirus related to Dengue virus, yellow fever virus and West Nile virus. It is Considered an emerging arbovirus transmitted by mosquitoes of the genus Aedes. It first identified in 1947 in the Zika Forest in Uganda, isolated on rhesus monkey used for the study the yellow fever virus. Sporadic cases have Been Detected in African countries and at the end of the 70's in Indonesia. In 2007 epidemics were described in Micronesia and other islands in the Pacific Ocean and more recently in Brazil. Clinical picture is characterised as a dengue-like syndrome, with abrupt onset of fever and an early onset skin rash, pruritic Often. Occasionally the disease Has Been associated with Guillain-Barré syndrome. Nevertheless, until now deaths and complications Caused by the disease are not reported. The diagnosis can be Performed by PCR or by IgG and IgM antibodies detection. The rapid spread of the virus and its epidemic potential are especially problematic in countries where there are the circulation of other arboviruses which imposes difficulties in the differential diagnosis and healthcare burden. Control measures are the same

recommended for dengue and chikungunya which are based in health education and vector control.¹

Etiology

The Zika virus (ZIKV) belongs to Flaviviridae family and the genus flavivirus is therefore related from an evolutionary point of view with other arbovirus transmitted by mosquitoes, as are the dengue virus, yellow fever (YFV) and viruses West Nile. It is a virus with a genome of ribonucleic acid (RNA) of simple positive polarity chain. Although not known to virion structure, compared to other known flavivirus, this must be limited by a co lipid envelope derived from the endoplasmic reticulum of cells in which these viruses replicate, restricting this housing externally with a capsid structure and symmetry, consisting of the C protein and the viral genome.²

Zika virus, has a positive-sense, single-stranded RNA genome approximately 11 kilobases in length. The genome contains 5' and 3' untranslated regions flanking a single open reading frame (ORF) that encodes a polyprotein that is cleaved into three structural proteins : the capsid (C), premembrane / membrane (prM), and envelope (E), and seven non-structural proteins (NS1, NS2A, NS2B, NS3, NS4A, 2K, NS4B, and NS5). A previous genetic study using nucleotide sequences derived from the NS5 gene indicated three ZIKV lineages : East African (one strain examined), West African (three strains examined), and Asian (one strain examined).

¹Consultant Physician
Care Hospital, Nagpur.

Address for Correspondence -

Dr. Sandeep Kharkar

E-mail : drsandeep2k@yahoo.com

The viral envelope contains the two surface proteins (designated M and E) and, additionally, the viral genome encodes number of other proteins, non-structural di-tas that either have enzymatic activity (NS3 : RNA helicase and protease and NS5 : RNA polymerase, RNA-dependent) or perform regulatory functions (control replication, transcription, translation and immune response) during the replication intracellular.²

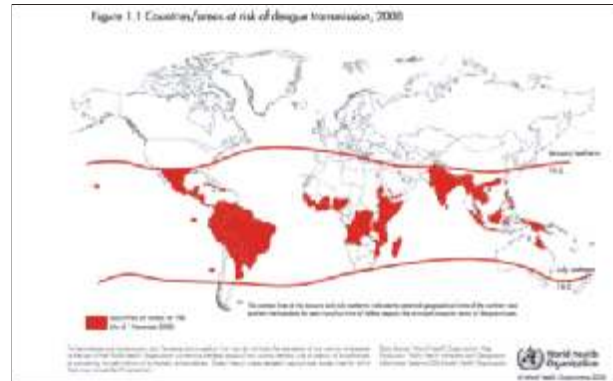Disease distribution

After isolation of the virus in 1940s, it was detected the first cases of infection ZIKV in humans in 1952 in Uganda.³ 1953 were also detected cases in Nigeria and 1956 mosquitoes *Aedes aegypti* species were infected laboratory resulting in successful transmission of the virus in mice by 60% of cases. in the 1960s, individuals with positive serology for ZIKV continued to be identified in serological surveys conducted in Nigeria and also in patients with fever for FMD epidemic in 1970. Between the years 1975 to 1977 were found serological and virological evidence of infection ZIKV in Sierra Leone, Nigeria, Senegal, Gabon, Costa Mar me in African Central.^{3,4}

The first evidence of virus circulation outside the African continent took place between the years 1977 and 1978, when cases of acute febrile illness were admitted to a hospital in Indonesia, and found antibodies in serum ZIKV 30^{5,6}. In February 2014, for the first time in the Americas, cases were reported in Easter Island (Chilean territory in the Paci Ocean Co), probably related to the outbreak in Micronesia and PF. In 2015 was confirmed virus circulation in northeastern Brazil from viral isolation in suspected cases of dengue.^{7,8,9}

Recently, the Ministry of Health of Brazil published a note that cases of the disease had been confirmed in eight states of the country, including the North, Northeast and sudpste

Fig. 1 : shows the countries where it already became clear the presence of infection in zero epidemiological surveys and indigenous transmission of the disease.



Clinical manifestations of infection caused by ZIKV, the information is limited to descriptions of isolated cases or series of cases in epidemic situations. The incubation period ranges from three to 12 days after the mosquito bite infected similarly to that described for other arboviroses¹⁰ Clinical manifestations of the disease can vary depending on location, and often a syndrome 'type-dengue'. asymptomatic infections are also described from survey results serological.¹¹⁻¹²

McNamara 7 described the first three human cases of infection ZIKV in 1954 in Nigeria, associated with jaundice. However the location was endemic for malaria and FA and therefore it was not possible to differentiate between the manifestations of the disease ZIKV other diseases. Later, Bearcroft³⁵ induced infection in healthy volunteer through exposure to *Ae. aegypti* infected; the patient presented with a fever especially and self-limited without rash, three days after the inoculation. In fact, this seems not experimentally infected individuals have developed viremia sufficiently intense to allow transmission of the ZIKV *Ae. Aegypti* that about him fed.

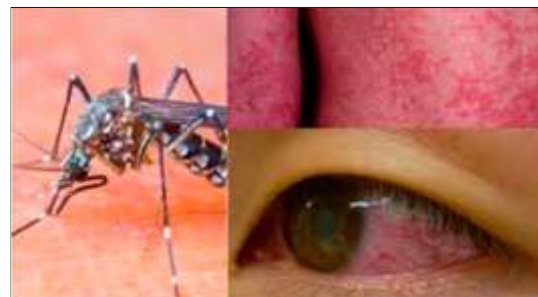

Fig. 2 : rash caused by infection Zika virus and conjunctivitis

Descriptions of cases of the disease in Africa in the following years featured the disease ZIKV as a febrile episode of acute onset, accompanied by mild headache, emergence of maculo-papular rash pruritic, on the second day, involving the face, trunk, limbs, palms and soles.

The diagnosis was confirmed by clinical and epidemiological criteria and negative serology for dengue virus. Fever gives a day or two after the onset of the rash, which may persist for two to 14 days (average duration of six days).^{13,14}

Usually the disease is low, but in some cases reported in Brazil was high, reaching 39 C. 5 are reported myalgia, joint pain and mild backache, but unlike the cases of chikungunya, the pain is less intense and more affect hands , knees and ankles. Usually their disappearance occurs about a week, with an average duration of three to five days.¹² Conjunctivitis has been commonly reported and, characteristically, has no pus. There may be other manifestations as anorexia, nausea, vomiting, dizziness and back-pain orbital^{15,16}

It can be assumed that the infection by ZIKV is benign, but as the epidemic that occurred in the PA, in Brazil there have been many cases of Guillain-Barré syndrome (GBS), which came a few days after the development of clinical the infection. The triggering mechanism of this condition is not yet

known, a likelihood that autoimmune phenomenon as observed in other infections. So far there has been no death registration in patients who developed GBS, although some cases have required treatment in intensive care units. Nevertheless, the association between infection and ZIKV GBS still lacks verification through analytical studies¹⁶

Information about the hematological and biochemical changes in the disease ZIKV are scarce in the literature. In some case reports are described increased lactate dehydrogenase and C-reactive protein. There may be leukopenia and thrombocytopenia.¹⁵

The diagnosis was confirmed by clinical and epidemiological criteria and logical negative serology for dengue virus.¹³

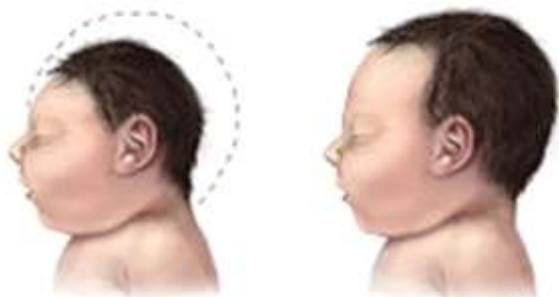
The differential diagnosis is made primarily with dengue and chikungunya. The rash illness caused by virusesT like Human parvovirus B19 infection by the Epstein-Barr virus, measles and rubella among others should also be investigated for their high transmission capacity in community . The infection ZIKV should also be considered in cases of post-travel fever in individuals returning from climates tropical.

There are no known cases of reinfections by ZIKV if thinking that an infection gives permanent immunity

Symptom	Dengue	Chikungunya	Zika
fever	+++	++	+
mayalgia	+++	++	+
exanthema	+	++	+++
arthralgia	+/-	+++	+
conjunctivitis	-	++	+++
shock	+++	+/-	-
neutropenia	++	+	SI
headache	++	+	+/-
dyscrasias	++	+/-	-
thrombocytopenia	+++	+/-	+/-
Lymphopenia	++	+++	SI

Table 1 : most common clinical manifestations fever caused by dengue virus, chikungunya and Zika virus

Pregnancy



Microcephaly

It is believed that the disease may be spread from mother-to-child in the womb and cause microcephaly. This is not yet confirmed, but there are a very few well documented reports.

In November 2015, reports from the Brazilian Health Ministry found two cases in Northeastern Brazil of severely affected babies in whom amniocentesis confirmed the presence of the Zika virus in the amniotic fluid. The ultrasound findings showed that both babies had a small head circumference (microcephaly) due to the destruction of different parts of the brain. One of the fetuses was also found to have calcifications in their eye and microphthalmia. Another study in an autopsy of a microcephalic fetus found Zika virus DNA as well as pathological damage in only the brain and not other organs, suggesting that the virus is neurotropic.

Investigators have also found evidence of eye abnormalities such as chorioretinal scarring in newborns with Zika-associated microcephaly. These lesions could lead to significant vision loss. It is still unclear whether this can happen in Zika exposed newborns that do not have microcephaly.

Laboratory diagnosis

Due to the absence, so far, commercial tests for serological diagnosis of infections ZIKV, the diagnosis of acute infection with this virus may be performed by RT-PCR (amplification by reacting polymerase chain, preceded by reverse transcription) directly from RNA extracted from patient serum, preferably harvested until the sixth day of disease. However, in the case of Yap island

epidemic virus was identified (via the viral genome cation amp) at the 11th day after onset of symptoms.^{17,18} The virus may also be detected by molecular techniques applied in other body fluids such as saliva and urine.

IgM antibodies can be found on the third day of illness and IgG antibodies should be investigated in acute and convalescent serum.¹⁷ A problem in relation to the serology is the possibility of cross-reactivity as a result of previous infection by other flavivirus.^{17,18} Nevertheless, several studies that have been reported or qualitative ratings or quantitative, the presence of anti-ZIKV antibodies in biological samples, and some of the techniques employed are not standardised techniques being used in laboratory specific contexts (technical in-house).

Despite the existence of diagnostic tests, its use is still very limited because there is no commercial kits available in the market. Therefore, the diagnosis is limited to government institutions involved in health surveillance, or teaching and research institutions. The detection of viral genomes by RT-PCR is the most sensitive method and specific to allow a diagnosis of infections to ZIKV, however these methods are not, as yet, fail-safe. Contrary to what happens to other viruses, the restricted circulation of the virus has limited knowledge about their actual genetic diversity, so there is a different probability of zero that the primers used in amp ZIKV genome cations can not allow the amp cations required (false negative amp cation). This case should be evaluated hereinafter.

Treatment

There are no vaccines in India (Bharat Biotech International, Hyderabad has developed vaccine) or antiviral drugs specific, and symptomatic treatment. The utilization of analgesics and antipyretics should be careful to avoid induction of adverse effects such as hepatopathy, nephropathy and allergies. The use of aspirin (salicylates) should be discouraged to prevent the induction of bleeding events in patients diagnosed with dengue erroneously as infections by ZIKV under clinical diagnosis not be conclusive and even serological test present possibility of failure.

The intense itching that accompanies the rash has been reported by patients as a serious discomfort. The therapeutic approach to relieve symptoms can start-up with the guidance of avoiding hot baths, excessive use of soap and proper hydration of the skin. If there is no satisfactory answer are recommended cold baths and the use of cooling lotions containing calamine or menthol. The pathogenesis of cutaneous manifestations is still unclear, so the use of older antihistamines can be helpful in the patient more for that cause sedation than for his performance in the cause of pruritus. Corticosteroids should not be used for is unknown its effectiveness and the regression of this symptom.

GBS must be addressed in a conventional manner. The diagnosis is made by progressive weakness of finding two or more members, exiarrre and evolution in a maximum of four weeks. The CSF analysis may show increased protein and low cellularity (albumin-cytological dissociation). Suspected patients should be monitored in intensive care units at risk of progression to paralysis of the respiratory muscles. Therapeuticoptions for GBS include plasmapheresis or intravenous hyperimmune immunoglobulin both are expensive, but decrease the time.

Control measures

The *Aedes aegypti* is a highly synanthropic mosquito, which takes advantage of peri domestic environments and even can make your blood meals inside human habitations. Considering that is one of the vectors ZIKV and given that vector control measures based on the use of insecticides can be complicated by (i) financial constraints, (ii) logistical issues, (iii) regulation fastened to the use of insecticides and/or (iv) spreading resistance in the vector population, the removal of larvae breeding plays an important role in the control of this vector. Personal protective measures should be encouraged as well as use of repellent and installing screens on windows and doors. The health surveillance should prioritise the detection and investigation of suspected cases in order to interrupt transmission in problem areas. Individuals with active disease or recently should not donate blood.

References :

1. Haddow AD, AJ Schuh, Yasuda CY, Kasper MR, Heang V, Huy R, *et al.* Genetic characterization of Zika virus strains : geographic expansion of the Asian lineage. *Trop Dis.* 2012; 6: e1477.
2. The Faye, Freire DC, Iamarino A, Faye O, de Oliveira JV, Diallo M, *et al.* Molecular evolution of Zika virus During its emergence in the 20th century. *Trop Dis.* 2014; 8: e2636.
3. Zanluca C, Melo VC, Mosimann AL, GI Santos, Santos CN, Light K. First report of autochthonous transmission of Zika virus in Brazil. *Mem Inst Oswaldo Cruz.* 2015; 110: 569-72.
4. Dick GW. Epidemiological notes on some viruses isolated in Uganda; Yellow fever, Rift Valley fever, Bwamba fever, West Nile, Mengo, Semliki forest, Bunyamwera, Ntaya, Uganda S and Zika viruses. *Trans R Soc Trop Med Hyg.* 1953; 47:13-48.
5. Monath TP, DC Wilson, J. Casals The 1970 yellow fever epidemic in Okwoga District, Benue Plateau State, Nigeria. 3. Serological responses in persons with and without pre-existing heterologous group B immunity. *Bull World Health Organ.* 1973;49:235-44.
6. Saluzzo JF, Gonzalez JP, JP Hervé Georges AJ. Serological survey for the prevalence of Certain arboviruses in the human population of the south-east area of Central African Republic. *Bull Soc Pathol Exotfiliales.* 1981;74:490-9.
7. RS Lanciotti, Kosoy OL, JJ Laven, Velez OJ, Lambert AJ, AJ Johnson, *et al.* Genetic and serologic properties of Zika virus associated with an epidemic, Yap State, Micronesia, 2007. *Emerg Infect Dis.* 2008;14:1232-9.
8. Musso D, Nilles EJ, Cao-Lormeau VM. Rapid spread of emerging Zika virus in the Paci c area. *ClinMicrobiolInfect.* 2014;20:O595-6.
9. Promed email [homepage of the internet]. Zika virus - Brazil (11) (various states), cases con rmadros. [Accessed 2015 Jul 20]. Available in : <http://www.promedmail.org/direct.php?id=20150612.3431199>.
10. AJ Haddow, Williams MC, Woodall JP, Simpson DI, LK Goma. Twelve isolations of zika virus from aedes (*Stegomyia*) *africanus* (theobald) taken in and above the Uganda forest. *Bull World Health Organ.* 1964;31:57-69.
11. Musso D, C Roche, Robin And Nhan T, Teissier A, Cao-Lormeau VM. Potential sexual transmission of Zikavirus. *Emerg Infect Dis.* 2015;21:359-61.

12. The Gezer, Henderson BE, Christensen S. multipurpose serological survey in Kenya. 2. Results of arbovirus serological tests. Bull World Health Organ. 1970;43:539-52.
13. Fagbami AH. Zika virus infections in Nigeria : virological and seroepidemiological investigations in Oyo State. J Hyg. 1979;83:213-9.
14. Bearcroft WG. Zika virus infection Experimentally induced in the human volunteer. Trans R Soc Trop Med Hyg. 1956;50:442-8.
15. Simpson DI. Zika virus infection in man. Trans R Soc Trop Med Hyg. 1964;58:335-8.
16. Oehler and Watrin L Larre P-LeparcGoffart I Lastere S Valour F, et al. Zika virus infection complicated by Guillain-Barre syndrome - case report, French Polynesia, December 2013. Euro Surveill. 2014;19.
17. Zammarchi L, Stella G Mantella A, Bartolozzi D, D Tappe, Günther S, et al. Zika virus infections imported to Italy : clinical, immunological and virological findings, and public health implications. Clin Virol. 2015;63:32-5.
18. Zammarchi L, Tappe D, C Fortuna, Remoli ME, Günther S, G Venturi, et al. Zika virus infection in a traveler returning to Europe from Brazil, March 2015. Euro Surveill. 2015; 20.