

## A Case of Eosinophilic Ascites

Vikas Ratnaparkhe<sup>1</sup>, Rajashree Ratnaparkhe<sup>2</sup>, Ravindra Patwadkar<sup>3</sup>

### ABSTRACT

Eosinophilic Gastroenteritis is a rare gastrointestinal (GI) disorder characterized by nonspecific GI symptoms, peripheral eosinophilia, and eosinophilic infiltration of the intestinal wall. The disorder is classified into mucosal, muscular, and sub-serosal types, depending on the clinical picture and the depth of eosinophilic infiltration within the GI wall. Sub-serosal disease, which is complicated by ascites, usually results in the most severe clinical form of eosinophilic gastroenteritis and requires early corticosteroid therapy. In such cases, a favorable outcome can be achieved after a short course of corticosteroids. We present a 27 yr. male presented with slowly progressive painless abdominal distension of three weeks duration not responding to treatment. His physical examination revealed moderate ascites. All relevant clinical investigations were normal. Ascitic fluid analysis showed significant eosinophilia. Subsequent treatment with oral prednisone resulted in the resolution of disease and ultrasonographic normalization within a span of two week. Despite its rarity, eosinophilic gastroenteritis needs to be recognized by the clinician because the disease is treatable, and timely diagnosis and initiation of treatment could be of major importance. One has to rule out worm infestation by stool examination and Chrug-Strauss syndrome by ANCA. Peritoneal dialysis is obvious cause if associated.

**Keywords :** eosinophilic ascites, eosinophilic gastroenteritis

### Introduction :

Eosinophilic gastroenteritis (EGE) represents a member of a family of diseases that includes eosinophilic esophagitis, gastritis, enteritis, and colitis, collectively referred to as eosinophilic gastrointestinal (GI) disorders. EGE is a rare disease characterized by focal or diffuse eosinophilic infiltration of the GI tract, especially the stomach and duodenum. It has vague, nonspecific symptoms, including nausea, vomiting, abdominal pain, diarrhea, weight loss, ascites, and malabsorption.<sup>1</sup> There is no single diagnostic test or procedure that would point directly to the diagnosis, and there are no strict or uniform diagnostic criteria.<sup>2</sup> Despite its rarity, eosinophilic gastroenteritis needs to be recognized by the clinician because this treatable disease can masquerade as irritable bowel syndrome.

### Case Report :

A 27 years old male, farmer by occupation presented

with complaints of sudden onset slowly progressive painless abdominal distension of 20 days duration, to treatment. He denied any history of recent fever, chills, night sweats, weight loss, and change in bowel habits, sick contacts, and consumption of raw food. In addition, he denied any chest pain, shortness of breath, joint swelling and skin rash. There was no history of recent travel. The patient was not taking any prescribed or over the counter medications or herbal compounds, and denied a history of allergies to food or medication. No history of fever, cough, dyspnoea his bowel bladder habits were normal. He was a tobacco chewer. His per abdominal examination revealed distention with diffuse tenderness, moderate ascites without organomegaly and with normal bowel sounds. Other systems were within normal limits.

His hematological investigations revealed Leucocytosis TLC 20350/mm<sup>3</sup>. DLC was Neutrophil 70%, Lymphocytes 16%, Monocytes 5% and eosinophils 7%. His KFT, LFT, S proteins with A/G ratio and thyroid profile and stool examination was within normal limits. HIV and ANCA were negative and USG abdomen revealed moderate ascites with mild splenomegaly. His ascitic fluid examination showed presence of coagulum on gross

<sup>1,2,3</sup>Consultant Physician, Hedgewar Rugnalaya, Aurangabad

*Address for Correspondence -*

Dr. Vikas Ratnaparkhe

E-mail : vikasrr25@gmail.com

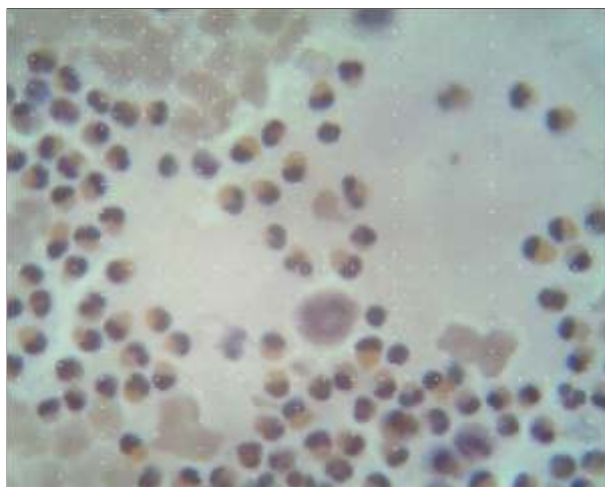
Received on 26th August 2017

Accepted on 13th December 2017

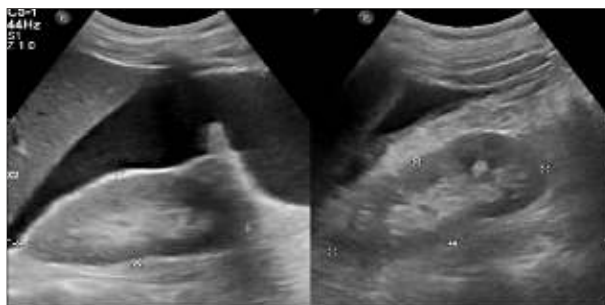
examination. Ascitic fluid revealed WBC count 4-5 / hpf and total count to be 300 cells/mm<sup>3</sup> with 85% eosinophils, 8% neutrophils, 55 lymphocytes and 2% monocytes. Ascitic fluid protein was 4.81 gm% and was negative for malignant cells. These findings were consistent with diagnosis of eosinophilic ascites. This constellation of clinical presentation and cytological findings were suggestive of eosinophilic gastroenteritis.

Patient was started on prednisolone 40 mg / day and antihelminthic. He responded dramatically. Two weeks later the prednisone was tapered off over a 2-week period. After the completion of the steroids, the patient's abdominal pain and ascites completely resolved and patient is asymptomatic till date. Eosinophilic ascites may be a part of idiopathic hypereosinophilic syndrome where blood also has hyper eosinophilia as was present in our patient.

**Figure 1 : Microphotographs showing predominantly eosinophils with occasional mesothelial cell. (Pap stain 100 x)**



**Figure 2 : Abdominal USG showing moderate ascites with septations with prominent bowel loops with thickened walls**



## Discussion :

Eosinophilic ascites is a rare disorder characterized by eosinophil rich inflammation of the gastrointestinal tract in the absence of known causes for eosinophilia such as malignancy, allergy, parasitic infestation, Churg Strausse syndrome or HTLV infection. Eosinophilic gastroenteritis (EGE) is a rare condition characterized by recurrent eosinophilic infiltration of portions of the GI (gastrointestinal) tract presenting with nonspecific GI symptoms in association with peripheral eosinophilia. Eosinophilic tissue infiltration can affect any of the three layers of the digestive apparatus with symptoms varying according to the affected layer. The most common grouping of EGE based on the involved layer of the GI tract is known as Klein's classification, which describes three subtypes of EGE (mucosal, muscular, and subserosal), with some degree of overlap.<sup>3</sup> Data are insufficient with regard to the true prevalence of EGE and each of its subtypes. However, the mucosal form is the most common followed by muscular and lastly subserosal.<sup>4</sup>

The prevalence of the subserosal form of EGE varies in different studies. A clinico-pathological study of 40 patients with EGE showed a predominance of mucosal disease in 57% patients with muscular and subserosal disease accounting for 30% and 13% of cases, respectively.<sup>5</sup>

Clinical manifestations depend on the affected layers and range from barely perceptible symptoms to intestinal obstruction or ascites. The most common mucosal form of EGE manifests with abdominal pain, nausea, vomiting, diarrhea, sometimes with hematochezia, and protein losing enteropathy, which may lead to weight loss and malnutrition. Muscularis involvement results in gut wall thickening and may lead to obstruction. The serosal form is the most unusual, and leads to EA. EA is often accompanied by pleural effusion and less frequently by ileus formation. Our patient also had right sided pleural effusion. It may take a relapsing remitting course in one fourth of patients.<sup>6</sup>

The etiopathogenesis of EGE is not clear. It seems to be result of complex interplay of environment,

genetics and the immune system; an association between EGE, collagenoses, allergy and hypereosinophilic syndrome has been reported<sup>1</sup>. There is no single diagnostic test or procedure that would point directly to the diagnosis of EGE, and there are no strict or uniform diagnostic criteria for it. Hence diagnosis requires high index of suspicion. When it is suspected on the basis of clinical presentation or the results of tissue biopsy, other causes of hypereosinophilia, should first be excluded. Diagnostic evaluation of the patient with suspected EGE should include complete blood cell count and differential, erythrocyte sedimentation rate, c reactive protein, amylase, stool studies for ova and parasites, upper and lower gastrointestinal endoscopy with biopsies, bone marrow biopsy, allergen studies (skin testing and rasts), and IgE and IL-5 levels. In the presence of ascites, paracentesis should be performed, and the ascitic fluid should be sent for cytology, cell count and differential, gram stain, culture, including culture for tuberculosis, glucose, protein, albumin, lactate dehydrogenase, IL-5, and IgE levels.<sup>7</sup> In eosinophilic ascites there is elevation of IL-5 in ascitic fluid, but not in the serum.<sup>8</sup> Ascitic fluid eosinophilia and a dramatic response to treatment with steroids indirectly confirm the diagnosis of EGE and EA<sup>6</sup> Abdominal ultrasound and computer tomography may demonstrate intestinal wall thickening, ascites, pleural effusions, and hepatosplenomegaly in patients with EGE. Some patients experience spontaneous resolution of symptoms, others have a relapsing remitting course and require long term treatment with steroids, usually at a low dose<sup>9</sup> Enteric-coated budesonide and sodium cromoglycate, a mast cell membrane stabilizer, have been used successfully for treatment of some atopic cases of EGE. Montelukast, a leukotriene receptor inhibitor, has been successfully used in treatment of serosal EGE. Omalizumab and mepolizumab, anti-IgE and anti-IL-5 monoclonal antibodies respectively, have shown promising results in the treatment of patients with EGE in clinical trials<sup>9</sup> However, long-term steroid therapy is sometimes

required to prevent reoccurrence of the EGE and EA, and steroid sparing treatment options should be considered.

### Conclusion :

This case report reviews some of the characteristic clinical, laboratory, and cytological findings of a rare, readily treatable, and easily missed disease. Owing to the relatively nonspecific symptoms, this diagnosis should be considered in patients with ascites of unclear etiology, nonspecific bowel thickening by imaging studies and otherwise, negative workup for parasitic infection and malignancy. Although peripheral blood or ascitic fluid eosinophilia is suggestive, its absence does not exclude the possibility of this diagnosis. Furthermore, prompt therapy with low-dose prednisone may reduce the duration and severity of symptoms. Thus, an awareness of this condition and a timely diagnosis and initiation of treatment could be of major importance.

### References :

1. Baek MS, Mok YM, Han WC, Kim YS. A patient with eosinophilic gastroenteritis presenting with acute pancreatitis and ascites. *Gut liver*. 2011;8:224-7.
2. Cuko I, Bilaj F, Bega B, Barbullushi A, Resuli B. Eosinophilic ascites, as a rare presentation of eosinophilic gastroenteritis. *Hippokratia*. 2014; 18:275-7.
3. Agostino A, Parenzi A. Eosinophilic gastroenteritis. A case with predominant involvement of mucosal and muscular layers. *Minerva med*. 1994;85:655-8.
4. Durieul I, Nove-Josserand R, Cathebras P, Durand DV, Rousset H, Levrat R. Eosinophilic ascites 2 new case reports. *Rev med internet* 1992;13:446-8.
5. Talley N, Shorter RG, Phillips SF, Zinsmeister AR. Eosinophilic gastroenteritis : a clinicopathological study of patients with disease of the mucosa, muscle layer and subserosal tissues *Gut*. 1990;31:54-58
6. Yoshikane H, Yatsuya H, Sakakibara A, et al. A case of eosinophilic peritonitis in which ascites interleukin 5 presented at a high level. *Hepato-gastroenterology* 2000; 47: 1588-1589.
7. Sunkureddi PR, Luu N, Xiao SY, Tang WW, et al. Eosinophilic enteritis with systemic lupus erythematosus. *South med j* 2005; 98: 1049-1052.
8. Guajardo JR, Plotnick LM, Fende JM, et al. Eosinophil-associated gastrointestinal disorders : A world-wide-web based registry. *J pediatr* 2002; 141: 576-581.
9. Chen MJ, Chu CH, Lin SC, et al. Eosinophilic gastroenteritis : clinical experience with 15 patients. *World j gastroenterol* 2003; 9: 2813-2816.