

Case Report**Systemic Lupus Erythematosus with Granulomatosis with Polyangiitis**Atul Rajkondawar¹, Nikhil Rathod², Amit Shrawankar³**ABSTRACT**

Granulomatosis with Polyangiitis is a rare disease which usually involves the Upper and Lower Respiratory tract as well as the Renal System. Here we discuss a case of Systemic Lupus Erythematosus with Granulomatosis with Polyangiitis in a 16 year old male who presented with Fever, Cough and Multiple joint pain. This case emphasizes on the rarity of such a combination of diseases in an Asian population.

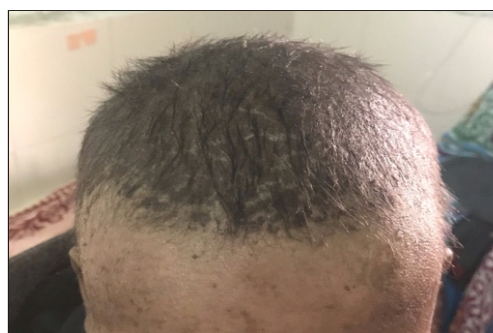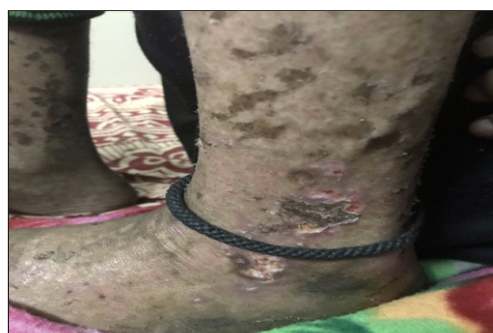Introduction :

Granulomatosis with polyangiitis (GPA) also known as Wegeners Granulomatosis is a disorder that causes blood vessel inflammation which can lead to organ damage^{1,2}. The kidneys, upper and lower airways are the most commonly affected areas of the body. GPA can occur in people of all ages. The peak age groups affected are from 40-60 years. It appears to affect men and women equally.

Case Report

16 year male patient presented with chief complaints of fever and multiple joint pain since 12 days and epistaxis since 2 days. Patient was asymptomatic 3 months back when he developed fever along with cough and was admitted in hospital. Patient was evaluated and was found to have cervical lymphadenopathy for which Fine needle aspiration cytology (FNAC) was done, that was suggestive of hematolymphoid malignancy. Patient was then referred to Cancer Institute to rule out leukemia, where Bone marrow aspiration was done, which was normal. Sputum examination done showed gram negative bacilli and gram positive budding yeast cells. Computed tomography of the thorax was suggestive of cavitary lesion in the Right Lung. Patient was referred to physician as a case of Pulmonary kochs. On further evaluation, patient gave history of repetitive episodes of rhinitis present

since childhood. Patient was conscious, well oriented to time, place and person. Patient was febrile, Pulse was 115/min, Respiratory Rate was 24/min, Blood pressure was 100/70 mmHg, Pallor was present. Hair loss was present. Nasal crustings were seen on anterior rhinoscopy and Legs showed multiple palpable purpura and ulcers. All the appendicular joints had features of arthritis. No icterus, clubbing, cyanosis. There was decreased air entry along with crepitations in the right infra mammary, infra scapular and infra axillary region. Abdomen was soft and non tender with no organomegaly. Heart sounds were normal with no adventitious sounds.

**Figure 1 : Non Cicatricial Hair Loss****Figure 2 : Multiple palpable purpura and ulcers**

¹Associate Professor, ²Junior Resident, ³Junior Resident
Department of Medicine
Government Medical College, Nagpur

Address for Correspondence -

Dr. Nikhil Rathod
E-mail : niks42@gmail.com

Received on 1st June 2020

Accepted on 15th June 2020

Laboratory studies included Hemoglobin-7.8 g/dL; WBC- 11.4×10^3 u/L; Platelets- 152×10^3 u/L; Urea-21 mg/dL, serum Creatinine-0.8 mg/dL; Serum Sodium-135 mEq/L; Serum Potassium-3.9 mEq/L. Chest X-ray was suggestive of Right lower lobe cavity; Ultrasonography of the abdomen and pelvis was normal; Absolute Eosinophil count normal; Anti Nuclear Antibodies (ANA) were strongly positive; Anti Nuclear Antibodies (ANA) blot showed Double stranded Deoxyribonucleotide antibodies (DsDNA) being strongly positive. As the patient had features of vasculitis Serum Antineutrophil cytoplasmic antibodies (ANCA) were done and was found to be p-ANCA positive; 2D echocardiography was normal; 24 hour urine protein was 840 mg/day. Sputum for acid fast bacilli was negative. Fresh Computed Tomography of the thorax was done which was suggestive of consolidation in bilateral lungs along with a cavity and fibrotic bands in the right lung. Skin biopsy from the leg lesions was suggestive of leukocytoclastic vasculitis with Lymphocyte predominance. Bronchoscopy was done and lavage was sent for investigations which was negative for Acid Fast Bacilli and fungal elements. On the basis of the history, examination and investigations, the diagnosis of SLE with Granulomatosis with polyangiitis was kept. Patient was started on intravenous injection Methylprednisolone 500 mg OD for 5 days followed by tablet prednisolone 40 mg once daily which was gradually tapered to 10 mg

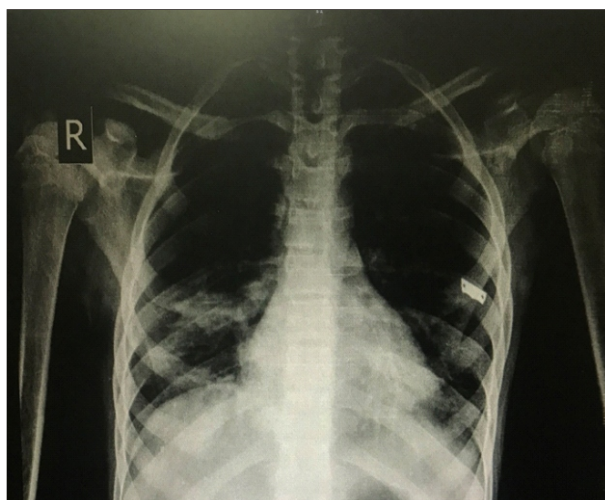


Figure 3 : Chest x-ray before treatment suggestive of Right Lower zone cavitation

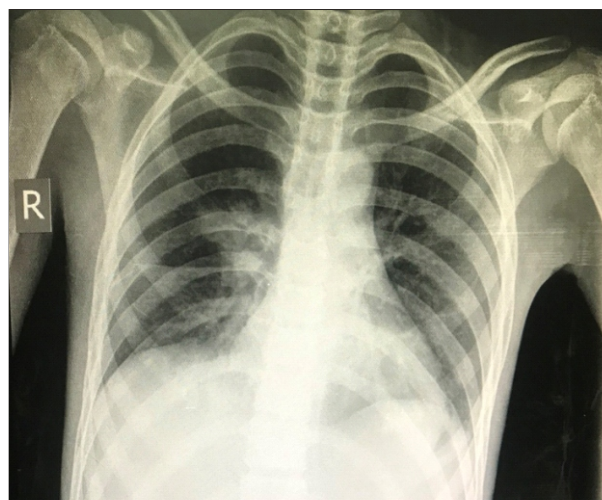

Figure 4 : Chest x-ray after treatment showing resolution of the cavity

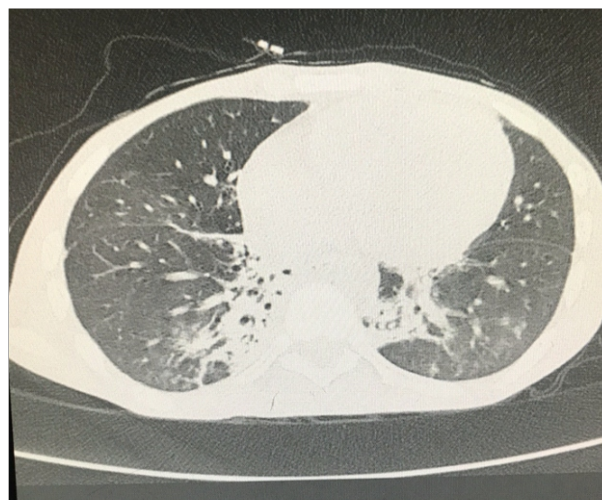


Figure 5 : Computed Tomography of thorax suggestion of consolidation in bilateral lungs and cavity and fibrotic bands in the right lung

once daily. With treatment, patient improved symptomatically.

Case Discussion :

Granulomatosis with polyangiitis previously known as Wegener's granulomatosis is a multisystem disorder which was first described by Klinger in 1933, followed by other investigators like Rossle in 1933, Wegener in 1936 and 1939 and Ringertz in 1947³. The prevalence of the disease is 3 per 1,00,000. It most commonly involves the upper respiratory tract causing rhinitis, sinusitis, otitis media, otorrhoea, nasal discharge, nasal ulcers,

nasal cartilage destruction^{5,6,7}. It also involves the lower respiratory tract causing subglottic stenosis, consolidation, pleural effusion, cavitations, nodules^{8,9,10}. Renal involvement may also be seen causing mild asymptomatic to fulminant Glomerulonephritis. Cutaneous lesions include leukocytoclastic vasculitis, urticaria, nodules¹¹. It can also involve the Nervous system causing Mononeuritis multiplex, sensory neuropathy, cranial nerve abnormalities, external ophthalmoplegia, sensorineural hearing loss^{12,13}. Ocular manifestations are reported in 28 to 58% of patients and it may include keratitis, conjunctivitis, scleritis, episcleritis, uveitis, retinal vessel occlusion and optic neuritis. Some rare findings include salivary gland, gastrointestinal and cardiac involvement. The American College of Rheumatology in 1990^{14,15} established the diagnostic criteria for GPA which included 1) Nasal or oral inflammation. 2) Abnormal chest x ray suggestive of nodules, cavities and fixed infiltrates. 3) Abnormal urinary sediment like microscopic hematuria with or without red cell casts. 4) Granulomatous inflammation on biopsy of an artery or perivascular area. Presence of atleast two of these criteria yielded a sensitivity of 88% and specificity of 92%. In our case the patient fulfilled the first two criteria. The closest differential in our case was Microscopic polyangiitis which got ruled out as the patient had Upper respiratory tract involvement. c-ANCA is usually seen in GPA but 20 percent of the cases can have p-ANCA positivity. In our case patient was p-ANCA positive which shows the rarity of the disease. Treatment includes Induction therapy for 3 to 6 months. For Non threatening disease : methotrexate 25 mg/week along with prednisone 1 mg/kg/day till 4weeks followed by tapering to 20 mg/day. In case of Life threatening disease: intravenous Rituximab 375 mg/m² once a week for 4 weeks with Prednisone 1 mg/kg/day till 4 weeks followed by tapering to 20 mg/day for 6 mths. or oral Cyclophosphamide 1.5 to 2 mg/kg/day with Glucocorticoids / intravenous cyclophosphamide 15 mg/kg every 2 week for 3 doses and then every 3 weeks for 3 to 6 months along with steroids^{16,17}. Maintenance therapy for 12 to 24 months which includes Azathioprine 2 mg/kg/day¹⁸ or Rituximab 500 mg at 0, 2nd week and at 6,12,18th month¹⁹ or

Methotrexate 0.3 mg/kg/week increase by 2.5 mg/week to 25 mg/week²⁰. This case shows the rarity of SLE occurring with GPA although there is no correlation between the two diseases.

References :

- Falk RJ, Gross, WL, Guillevin L, et al. Granulomatosis with polyangiitis : an alternative for Wegener's granulomatosis. *J Am Soc Nephrol* 2011; 22:587
- Jennette JC, Falk RJ, Bacon PA, et al. 2012 revised International ChapelHill Consensus Conference Nomenclature of Casculitides *Arthritis Rheum* 2013;65:1
- Lie JT. Illustrated histologic classification criteria for selected vasculitis syndromes. *Arthritis Rheum* 1990; 33:1074-87.
- Watts RA. Wegener's granulomatosis : unusual pre-sentations. *Hosp Med* 2000;61:250-3.
- Jennette JC, Falk RJ. Small-vessel vasculitis. *N Engl J Med* 1997; 337:1512.
- Seo P, Stone JH. The antineutrophil cytoplasmic antibody-associated vasculitides. *Am J Med* 2004; 117:39.
- Hoffman GS, Kerr GS, Leavitt RY, et al. Wegener granulomatosis: an analysis of 158 patients. *Ann Intern Med* 1992; 116:488.
- Gómez-Puerta JA, Hernández-Rodríguez J, López-Soto A, Bosch X. Antineutrophil cytoplasmic antibody-associated vasculitides and respiratory disease. *Chest* 2009; 136:1101.
- Solans-Laqué R, Bosch-Gil J, Canela M, et al. Clinical features and therapeutic management of subglottic stenosis in patients with Wegener's granulomatosis. *Lupus* 2008; 17:832.
- Savage CO, Winearls CG, Evans DJ, et al. Microscopic polyarteritis : presentation, pathology and prognosis. *Q J Med* 1985; 56:467.
- Daoud MS, Gibson LE, DeRemee RA, et al. Cutaneous Wegener's granulomatosis : clinical, histopathologic, and immunopathologic features of thirty patients. *J Am Acad Dermatol* 1994; 31:605.
- Garovic VD, Clarke BL, Chilson TS, Specks U. Diabetes insipidus and anterior pituitary insufficiency as presenting features of Wegener's granulomatosis. *Am J Kidney Dis* 2001; 37:E5.
- Czarnecki EJ, Spickler EM. MR demonstration of Wegener granulomatosis of the infundibulum, a cause of diabetes insipidus. *AJNR Am J Neuroradiol* 1995; 16:968
- Leavitt RY, Fauci AS, Bloch DA, et al. The American College of Rheumatology 1990 criteria for the classification of Wegener's granulomatosis. *Arthritis Rheum* 1990; 33:1101.
- Rao JK, Allen NB, Pincus T. Limitations of the 1990 American College of Rheumatology classification criteria in the diagnosis of vasculitis. *Ann Intern Med* 1998; 129:345.
- Stone JH, Merkel PA, Spiera R, et al. Rituximab versus cyclophosphamide for ANCA-associated vasculitis. *N Engl J Med* 2010; 363:221.
- Jones RB, Tervaert JW, Hauser T, et al. Rituximab versus cyclophosphamide in ANCA-associated renal vasculitis. *N Engl J Med* 2010; 363:211.
- Jayne D, Rasmussen N, Andrassy K, et al. A randomized trial of maintenance therapy for vasculitis associated with antineutrophil cytoplasmic autoantibodies. *N Engl J Med* 2003; 349:36.
- Guillevin L, Pagnoux C, Karras A, et al. Rituximab versus azathioprine for maintenance in ANCA-associated vasculitis. *N Engl J Med* 2014; 371:1771.
- Langford CA, Talar-Williams C, Barron KS, Sneller MC. Use of a cyclophosphamide-induction methotrexate-maintenance regimen for the treatment of Wegener's granulomatosis: extended follow-up and rate of relapse. *Am J Med* 2003; 114:463.