

## Atrial Septal Aneurysm : ECHO Surprise

Khot R S<sup>1</sup>

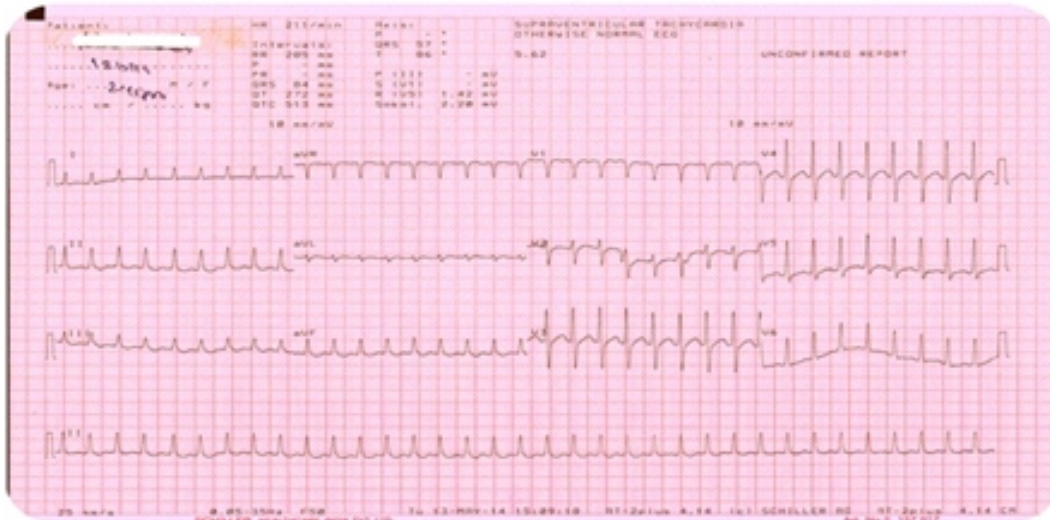


Figure 1 : Case 1 - ECG showing Supraventricular Tachycardia

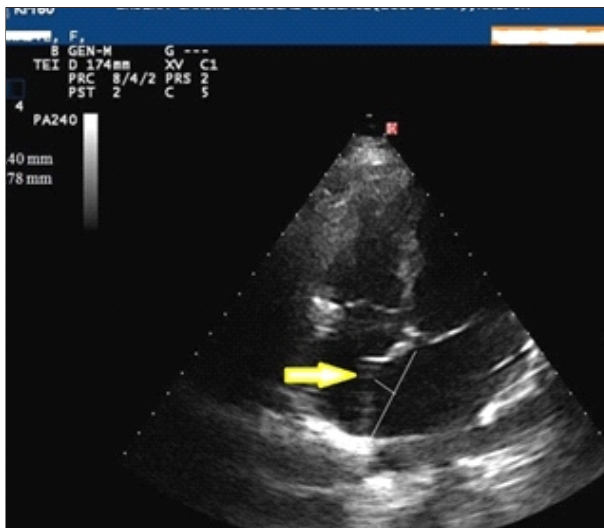

Figure 2 : Case 1- 2D Echo shows - An atrial septal aneurysm

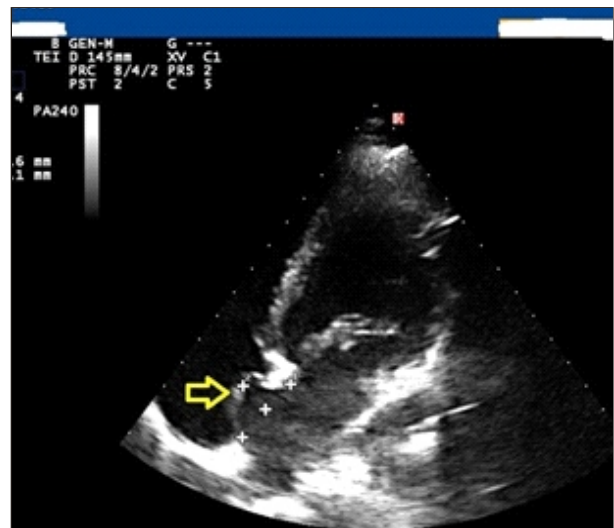


Figure 3 : Case 2 - 2D Echo showing - Type 1 RA atrial septal aneurysm - type 1 R

<sup>1</sup>Associate Professor  
Department of Medicine,  
Indira Gandhi Govt. Medical College, Nagpur

**Address for Correspondence -**

Dr. Rajshree S. Khot  
E-mail : rajashree.s.khot@gmail.com

Atrial septal aneurysm is a localized “saccular” deformity, generally at the level of the fossa ovalis, which protrudes to the right or the left atrium or on both sides. Albeit rare, atrial septal aneurysm is a well recognised cardiac abnormality. It is now frequently being picked up on routine echocardiography or during evaluation of ischemic stroke<sup>1</sup>.

First case, Ms. KM, a 17 yrs. old, female was repeatedly attending medicine outpatient department (OPD) for 8 months for chest discomfort and intermittent palpitations. She had 10-12 consultations and 10 Electrocardiograms (ECG) which were normal. On examination her vitals and systemic examination was normal. She took lot of analgesics but no relief. She also consulted a psychiatrist who gave her antidepressants which caused more somnolence and lethargy. She was admitted and was put on a cardiac monitor. She developed an episode of Supraventricular tachycardia (**Figure 1**) which reverted spontaneously. Her Transthoracic 2D Echocardiography (ECHO) with Doppler revealed an atrial septal aneurysm type 1 R (**Figure 2**). She was reassured and discharged on oral Metoprolol. She is asymptomatic and under regular follow up.

Second case, Mr. RS, a 22 year old male patient came to medicine OPD for a physical fitness certificate for job. He was asymptomatic and his clinical examination was normal. His ECG revealed T wave inversion in lead II, III and aVF. Hence he was referred for echocardiography. Transthoracic ECHO revealed an Atrialseptal aneurysm type 1 R (**Figure 3**). He was also reassured and given a medical fitness certificate. He is also under regular follow up.

An atrial septal aneurysm (ASA) is a rare but well recognized entity. Frequency of the anomaly in the general adult population is low (<1% & 2.2% by TEE). Atrial septal aneurysm may be isolated or associated with another anomaly. Commonest association is patent foramen ovale (PFO). Other associations are atrial septal defect, mitral valve prolapse, tricuspid valve prolapse, Marfans syndrome, Sinus of valsalva aneurysm and aortic dissection. Familial clustering of ASA has also been reported 1.

It is classified as : 1) Type 1R- bulging is in the right atrium only, 2) Type 2L- bulging is in the left atrium only, 3) Type 3RL- if the major excursion bulges to the right atrium and the lesser excursion bulges toward the left, 4) Type 4LR- Maximal excursion of the atrial septal aneurysm is toward the left atrium

with a lesser excursion toward the right atrium, 5) Type 5 - Atrial septal aneurysm movement is bidirectional & equidistant 1.

Most of the times ASA is clinically benign. Clinical manifestations attributed to ASA are 1) atrial arrhythmias and 2) arterial embolism. Atrial septal aneurysm can act as an arrhythmic focus, generating focal atrial tachycardias. Likewise our first case also had supraventricular tachycardia. Mechanism of increased prevalence of atrial tachyarrhythmia in ASA is not clear though redundancy of atrial septum could be responsible for pathogenesis of arrhythmia<sup>2</sup>. Thrombus formation may occur on the left atrial side of ASA which may embolize and cause an ischaemic stroke. Hence patients with stroke, even paediatric patients should be evaluated by ECHO for presence of ASA<sup>3</sup>.

Uncomplicated and isolated ASA requires no specific treatment other than follow up. Patients should be evaluated for presence of thrombus in aneurysm. In case of atrial arrhythmia, specific treatment is given. In case of embolic episode patient needs antiplatelet drugs and preferably oral anticoagulation for secondary prevention of cardioembolic episode. Shunt closure may be done in recurrent stroke<sup>4</sup>.

#### References :

1. Hanley PC, Tajik AJ, Hynes JK, Edwards WD, Reeder GS, Hagler DJ, Seward JB. Diagnosis and classification of atrial septal aneurysm by two-dimensional echocardiography : report of 80 consecutive cases. *J Am CollCardiol.* 1985;6:1370-138.
2. Russo V1, Rago A, Di Meo F, Papa AA, Ciardiello C, Cristiano A, Calabrò R, et al. Atrial Septal Aneurysms and Supraventricular Arrhythmias: The Role of Atrial Electromechanical Delay. *Echocardiography.* 2015 Mar 3. doi : 10.1111/echo.12908. [Epub ahead of print].
3. Mohd Razaq, Ravi Kumar Parihar, and Ghanshyam Saini. Atrial septal aneurysm and stroke. *Ann Pediatr Cardiol.* 2012 Jan-Jun; 5(1): 9899.
4. Michael Butterfield, Christine Riguzzi, Oron Frenkel, Arun Nagdev, From the Heart : Atrial Septal Aneurysm Identified on Bedside Ultrasound. *West J Emerg Med.* 2014 Sep; 15(6): 719720.