

Tubercular Rheumatism : A rare case of Poncet's DiseaseS M Gour¹, Nilesh Sonawane², Radha Munje³, Jitesh A⁴, Vandana P B²**ABSTRACT**

Poncet's disease (PD) is a form of reactive arthritis that develops in patients with active tuberculosis (TB). It is characterized by non-destructive symmetric polyarthritis. It is a rare disease and requires high index of suspicion for its early detection. Arthritis responds dramatically after institution of anti-tuberculous therapy. We report a case of a middle aged man who presented with symmetrical arthritis and was diagnosed to have Poncet's disease almost after one and half years.

Key-words : Tubercular rheumatism, Poncet's disease, Reactive Arthritis

Introduction :

India is endemic country for tuberculosis. Tuberculosis can present with various clinical features including multiple chronic joint pain. Involvement of joints by mycobacteria without any direct bacteriological involvement of joint, is called as Poncet's disease¹. It is defined as polyarthritis associated with visceral tuberculosis in which there is no bacteriological evidence of joint involvement themselves². Identifying such clinical presentation is very important because Patient remain without being treated for real underlying cause. With initiation of Antitubercular therapy, disease has favourable prognosis.

Case Report :

A 42 year old housewife presented to Chest OPD with complaint of bilateral multiple small and large Joint pain predominantly involving lower limb on and off since 1.5 years, complaints of cough with scanty mucoid expectoration and low grade fever since 6 weeks. She did not have history of rash over body or morning stiffness of joints. No history of any Viral exanthm. No family history of joint pain. She had consulted rheumatologist and received

depot preparation of Inj. Methylprednisolone via intramuscular route, Tab. Aceclofenac, Tab. Clonazepam, Tab. Gabapentin and nutritional supplements for her joint pain.

On examination patient was afebrile. R S examination revealed Right infrascapular crepts. There was no other significant finding except for Joint Swelling in left ankle and knee joint. Joint tenderness was present in both wrist, ankle and knee joint.

Investigation :

Before presenting to our OPD. Patients lab reports were Hb 12.4 gm%, TLC-10,000/mm³, DLC-N52L40E03M05, Her ESR was 90 mm at end of 1 hr (by Westergren's method). Biochemical parameters like LFT, sr. Creatinine, blood sugar level, Sr. Vitamin D and B12 level, Thyroid profile were all within Normal limits. ANA & RA factor were negative. USG abdomen was normal and colour Doppler of lower limb showed normal flow. Chest X-ray which-suggestive of right lower zone haziness (**Image 1**). Patients Sputum AFB smear examination was negative. CT thorax revealed multiple tiny nodular opacities in basal segment of right lower lobe and changes of consolidation seen in medial basal segment of right lower lobe s/o infective etiology (**Image 2**). Mantoux test showed induration of 5mm.

Patient was then Posted for fiberoptic bronchoscopy. Bronchoscopy was done as per Standard operational Procedure which showed endobronchial growth in subsegmental bronchus of

¹Associate Professor, ²Junior Resident, ³Professor and HOD, ⁴Assistant Professor
Department of Pulmonary Medicine, Indira Gandhi Government Medical College Nagpur.

Address for Correspondence -

Dr. Radha Munje

E-mail : radhamunje@yahoo.com

lower lobe (*Image 3*). Brochoalveolar lavage (BAL) and bronchoscopic biopsy was obtained. Molecular rapid diagnostic test-CBNAAT (Cartridge Based Nucleic Acid Amplification Test) of BAL clinched our diagnosis-Mycobacterium tuberculosis (MTB) detected Rif. Resistance not detected (*Image 4*). Histopathological Examination of biopsy Showed granulation tissue. Patient expelled a mass of tissue after bronchoscopy consisting of foreign body surrounded by granulation tissue on histopath. examination. This was consistent with history of aspiration of betel nut piece 4 months back-proving endobronchial growth as benign incidental finding

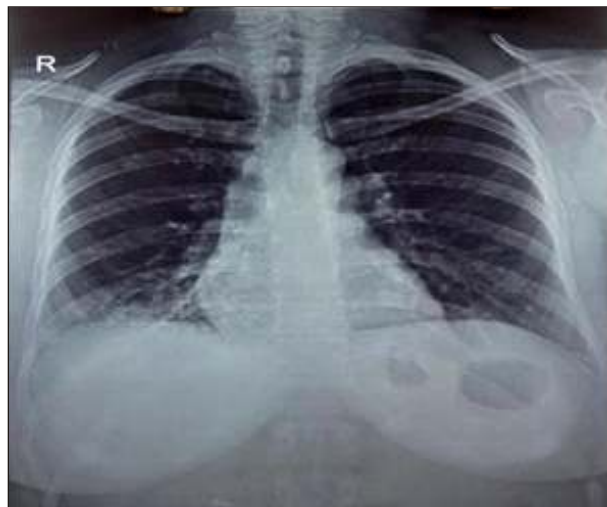


Image 1 : Right lower zone haziness

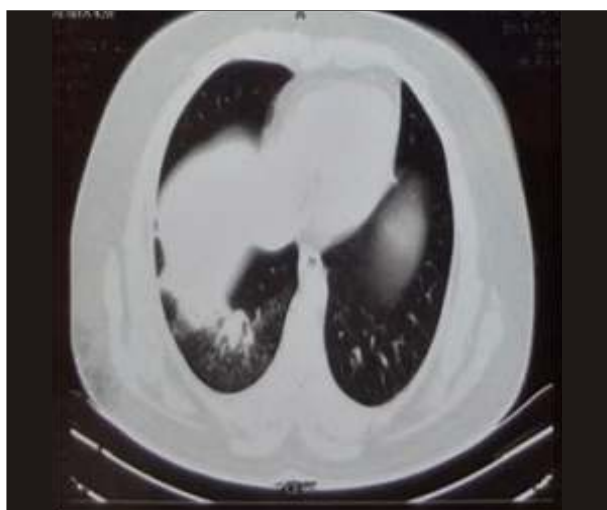

Image 2 : CECT Thorax Showing Involvement of medial basalsegment

secondary as reaction to foreign body (betel nut piece). Thus, detection of Mycobacterium with arthritis was consistent with diagnosis of Poncet's disease.

Patient was started on Daily Antitubercular regimen & was relieved from her Joint pain within first week of treatment. Patient is still in follow-up and remaining joint pain free since then.

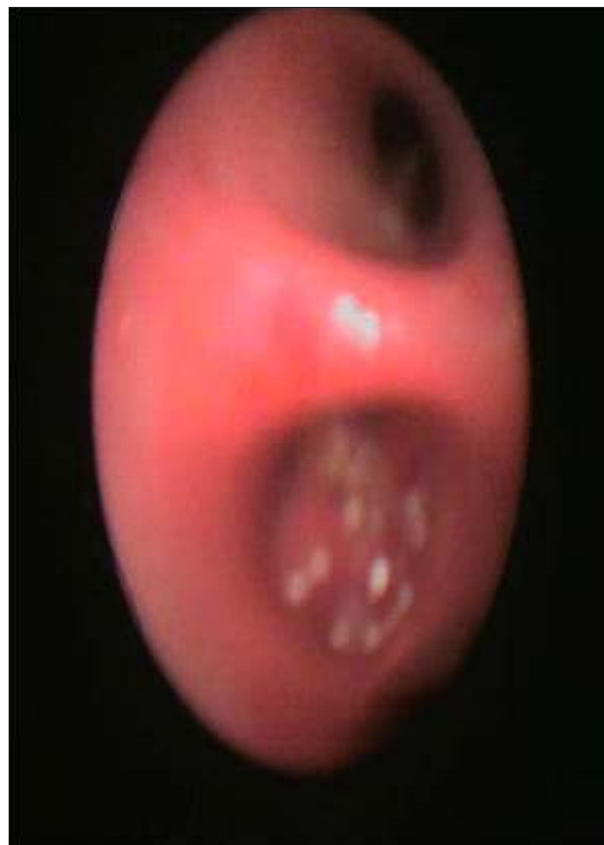


Image 3 : Endobronchial growth visible during bronchoscopy

Discussion :

Clinically when arthritis presents in middle aged female patient differential diagnosis includes rheumatoid arthritis (RA), reactive arthritis, undifferentiated arthritis. Among these reactive arthritis without actual involvement of joint by tubercular bacilli is known as Poncet's disease⁴. In year 1896, Poncet made an observation that-attacks of polyarthritis occurred in a 15 year old boy with suppurating tuberculous hip joint. He studied several such case and described a syndrome in year

Test Type: Specimen: BRANCHIALVEOLAR LA

Assay Information

Assay	Assay Version	Assay Type
mpet MTB-RF Assay U4	3	In Vivo Diagnostic

Test Result: **MTB DETECTED VERY LOW.**

Test and Analyte Result

Analyte Name	CI	EndPT	Analyte Result	Probe Check Result
Probe C	32.2	90.0	POS	PASS
Probe C	31.9	104.0	POS	PASS
Probe B	34.0	92.0	POS	PASS
Probe B	32.2	95.0	POS	PASS
SPC	35.2	240.0	NA	PASS
Probe A	31.9	89.0	POS	PASS
QC-1	0.0	0.0	NEG	PASS
QC-2	0.0	0.0	NEG	PASS

User: labindia

Status: Done

Expiration Date: 14/05/17

S/W Version: 4.4a

Cartridge S/N: 245520305

Reagent Lot ID: 19009

Notes: LAB NO - 748/15

Error Status: OK

Start Time: 21/07/16 11:13:19

End Time: 21/07/16 12:54:46

Instrument S/N: 805396

Module S/N: 647944

Module Name: A2

Errors: <None>

For In Vivo Diagnostic Use Only.

GeneXpert® Dx System Version 4.4a Page 1 of 8

Image 4 : CBNAAT report - Giving Rapid and specific diagnosis

1897 which bears his name i.e. Poncet's Disease². This disease is based on concept that joint was affected without being directly involved by microorganism itself. In 2007, Kroot et al reviewed literature for Poncet's disease, studied feature of 50 cases of Poncet's disease. He presented his conclusion in Journal of Rheumatology as "Aseptic polyarthrititis presumably reactive arthritis developing in presence of active tuberculosis in body"³. Zaitan et al described - a case of Poncet's disease whereby the patient had intermittent episodes of polyarthrititis (with remission in between) before developing cough and dyspnea. This underlining variable course of disease¹⁰.

Poncet's disease is a reactive polyarthrititis associated with non-articular tuberculosis. It is a form of reactive arthritis secondary to active Tuberculosis infection in body. It is rare in occurrence. The arthritis is aseptic and believed to occur due to a hypersensitive immune cell mediated response to the tubercular proteins, that result in an inflammatory response in the joint spaces. Despite the frequency of Tubercular infection is high and

presentation of disease in this form is rare as compared to tuberculosis cases, a genetic predisposition has been suggested in the pathogenesis mechanism⁴. Genes located within the MHC locus play an important role in the susceptibility to Poncet's disease⁶. Tuberculosis should be considered as differential diagnosis - whenever a patient has a polyarthropathy of obscure / unidentified cause⁷. Poncet's arthritis is non-destructive and resolves completely following anti-TB treatment¹³. Recently, the incidence of aseptic arthritis following intravesical instillation of bacille Calmette-Guérin (BCG) for bladder carcinoma was reported to be 0.40.8%, occurring generally after 48 weeks of BCG immunotherapy⁸. This occurrence can be considered similar to Poncet's disease.

Among important feature that differentiate, this entity from reactive arthritis is younger age of presentation and most important feature is response to anti TB treatment. It has a very favorable prognosis with antituberculosis drugs⁵. Other arthritis need treatment with anti-inflammatory agents including glucocorticoids and DMARDs. One has to often wait for months to see response to these drugs. Resolution of the arthritis with anti-TB drugs occurs in just a few days in Poncet's disease³.

Conclusion :

This case emphasise that an active search should be made for focus of tuberculosis in patient with history of joint pain specially in cases where patient is not improving with DMARD and symptomatic treatment.

References :

1. Malaviya AN, Shankar S, Arya V, Dhir V, Agarwal V, Pandya S, Shanmuganandan K, Chaturvedi VP, Das CJ. Indian Rheumatology Association consensus statement on the diagnosis and treatment of axial spondyloarthropathies. Indian Journal of Rheumatology. 2010 Mar 31;5(1):16-34.
2. Sri SS, Banginwar AS. Textbook of pulmonary and extra pulmonary tuberculosis.
3. Kroot EJ, Hazes JM, Colin EM, Dolhain RJ. Poncet's disease : reactive arthritis accompanying tuberculosis. Two case reports and a review of the literature. Rheumatology. 2007 Mar 1;46(3):484-9.
4. Chakraborty PP, Ray S, Selvan C, Bhattacharjee R, Mandal SK. Poncet's disease : An unusual presentation of

- tuberculosis in a diabetic lady. *World Journal of Clinical Cases*: WJCC. 2015 Apr 16;3(4):385.
5. Ariza-Prota M, Pando-Sandoval A, García-Clemente M, Casan P. Poncet's disease mimicking rheumatoid arthritis in a patient with suspected Crohn's disease. *Clinical case reports*. 2016 Jan 1;4(1):72-5.
 6. Lugo-Zamudio GE, Yamamoto-Furusho JK, Delgado-Ochoa D, Nuñez-Farfán RM, Vargas-Alarcón G, Barbosa-Cobos RE, Granados J. Human leukocyte antigen typing in tuberculous rheumatism : Poncet's disease. *The International Journal of Tuberculosis and Lung Disease*. 2010 Jul 1;14(7):916-20.
 7. Bloxham CA, Addy DP. Poncet's disease: para-infective tuberculous polyarthropathy. *British medical journal*. 1978 Jun 17;1(6127):1590.
 8. Chakraborty PP, Ray S, Selvan C, Bhattacharjee R, Mandal SK. Poncet's disease : An unusual presentation of tuberculosis in a diabetic lady. *World Journal of Clinical Cases* : WJCC. 2015 Apr 16;3(4):385.
 9. Ozgul A, Baylan O, Taskaynatan MA, Kalyon TA. Poncet's disease (tuberculous rheumatism) : two case reports and review of the literature [Case Study]. *The International Journal of Tuberculosis and Lung Disease*. 2005 Jul 1;9(7):822-4.
 10. Irmi ZI, Zaiton A, Faezah H. Reactive arthritis in tuberculosis : A case of Poncet's disease. *Malaysian family physician : the official journal of the Academy of Family Physicians of Malaysia*. 2013;8(1):24.